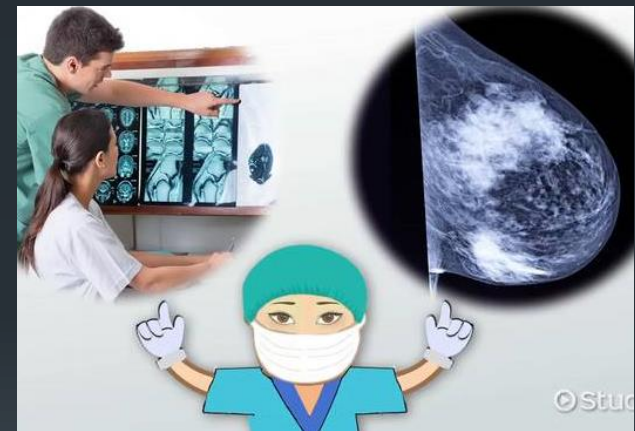

# Stereotactic biopsy and beyond: A radiologist's perspective



Kirti Kulkarni, MD (email: [kkulkarni@radiology.bsd.uchicago.edu](mailto:kkulkarni@radiology.bsd.uchicago.edu))  
Associate Professor of Radiology  
Director, Breast Imaging Fellowship  
Section of Breast Imaging  
University of Chicago, Chicago IL




THE UNIVERSITY OF  
CHICAGO





THE UNIVERSITY OF  
**CHICAGO**



IT'S A  
**RADIOLOGY**  
THING, YOU



THE UNIVERSITY OF  
CHICAGO



# Outline

## What goes before and after the stereotactic bx!

- Screening mammography guidelines
- What to do with calcifications in diagnostic clinic?
- BI-RADS
- Different types of calcifications and why we biopsy one over the other
- How do they look on MRI?
- How do we localize the lesion for the surgeon \*wire \*seed
- Specimen imaging



# Screening mammography guidelines

- Normal/Average risk: At age 40
- Who is high risk for breast cancer?

Women with greater than 20-25% lifetime risk

**BRCA 1** : 50-85% lifetime risk. **BRCA 2**: 45% lifetime risk. Mutations p53, PTEN. Li Fraumeni, Cowden, Bannayan-Riley-Ruvalcaba syndromes

Chest or mantle radiation between 10-30 years of age  
Recipients of >20 Gy or cumulative dose  $\geq 10$  Gy before age 30

Strong family history in absence of genetic mutations, including first degree relatives and young age at diagnosis



# BI-RADS

## Final Assessment Categories

Category		Management	Likelihood of cancer
0	Need additional imaging or prior examinations	Recall for additional imaging and/or await prior examinations	n/a
1	Negative	Routine screening	Essentially 0%
2	Benign	Routine screening	Essentially 0%
3	Probably Benign	Short interval-follow-up (6 month) or continued	>0 % but ≤ 2%
4	Suspicious	Tissue diagnosis	4a. low suspicion for malignancy (>2% to ≤ 10%) 4b. moderate suspicion for malignancy (>10% to ≤ 50%) 4c. high suspicion for malignancy (>50% to <95%)
5	Highly suggestive of malignancy	Tissue diagnosis	≥95%
6	Known biopsy-proven	Surgical excision when clinical appropriate	n/a



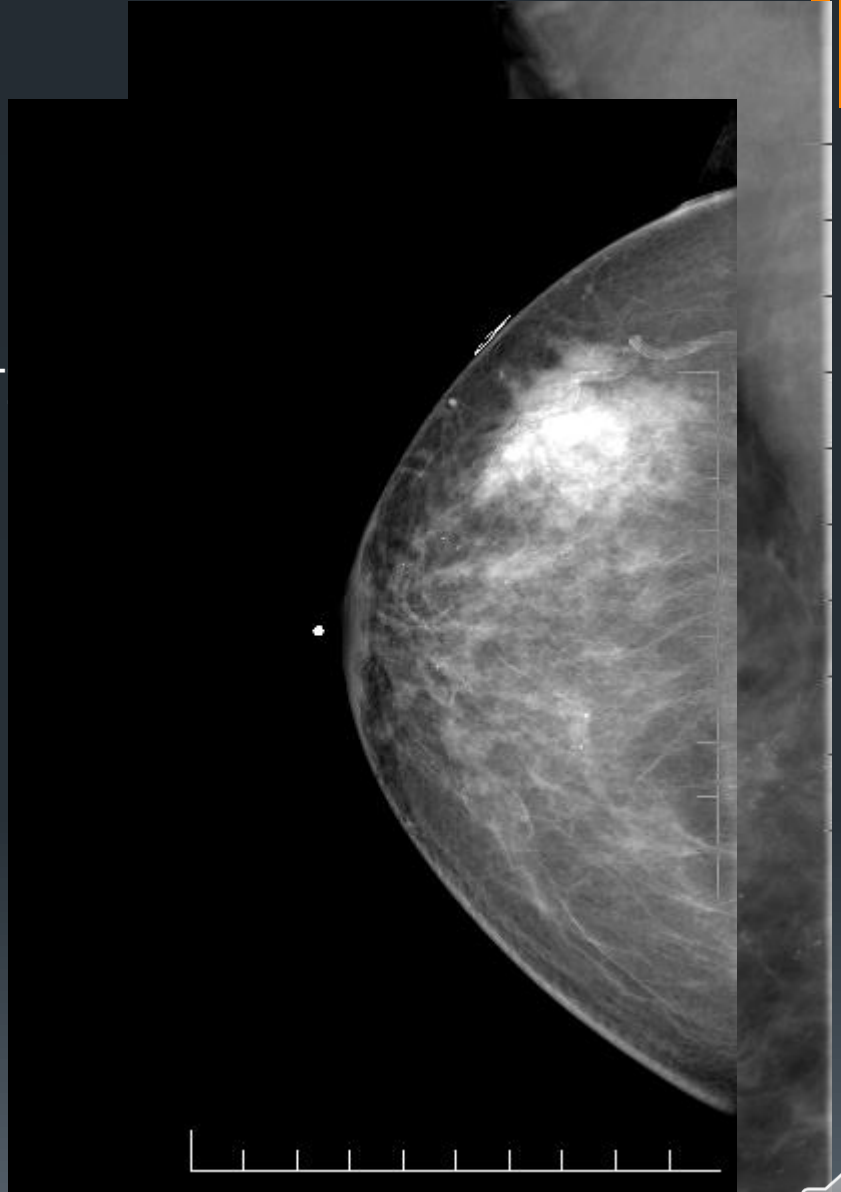# Just another day!

MASS/focal asymmetry

CALCIFICATIONS

ARCHITECTURAL DISTORT

What are we looking for?



ADDITIONAL DIAGNOSTIC MAMMOGRAM/ US WORK UP

ARCHITECTURAL  
DISSECTION

Yes, US

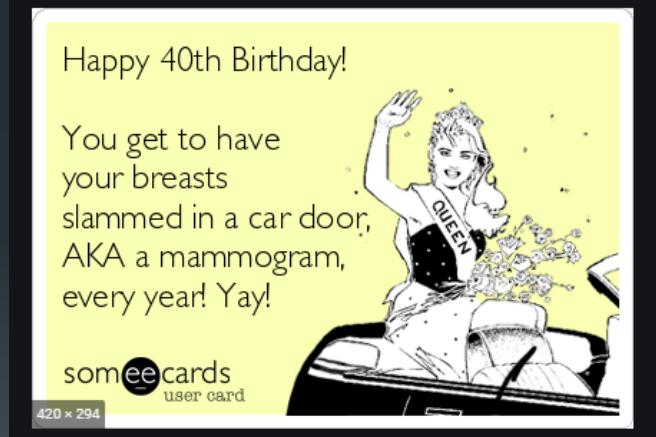
US GUIDED CORE  
INVASIVE COMPONENT

No, US

STEREOTACTIC Bx

ALWAYS ASK FOR COMPARISON

Two tools!



# How to work up calcifications?

## "MAKE DO WITH WHAT YOU HAVE": THE VALUE OF STEREOTAXIC BREAST BIOPSY

Formal Indications for Stereotaxic Biopsy:

BI-RADS® Category 5

BI-RADS® Category 4

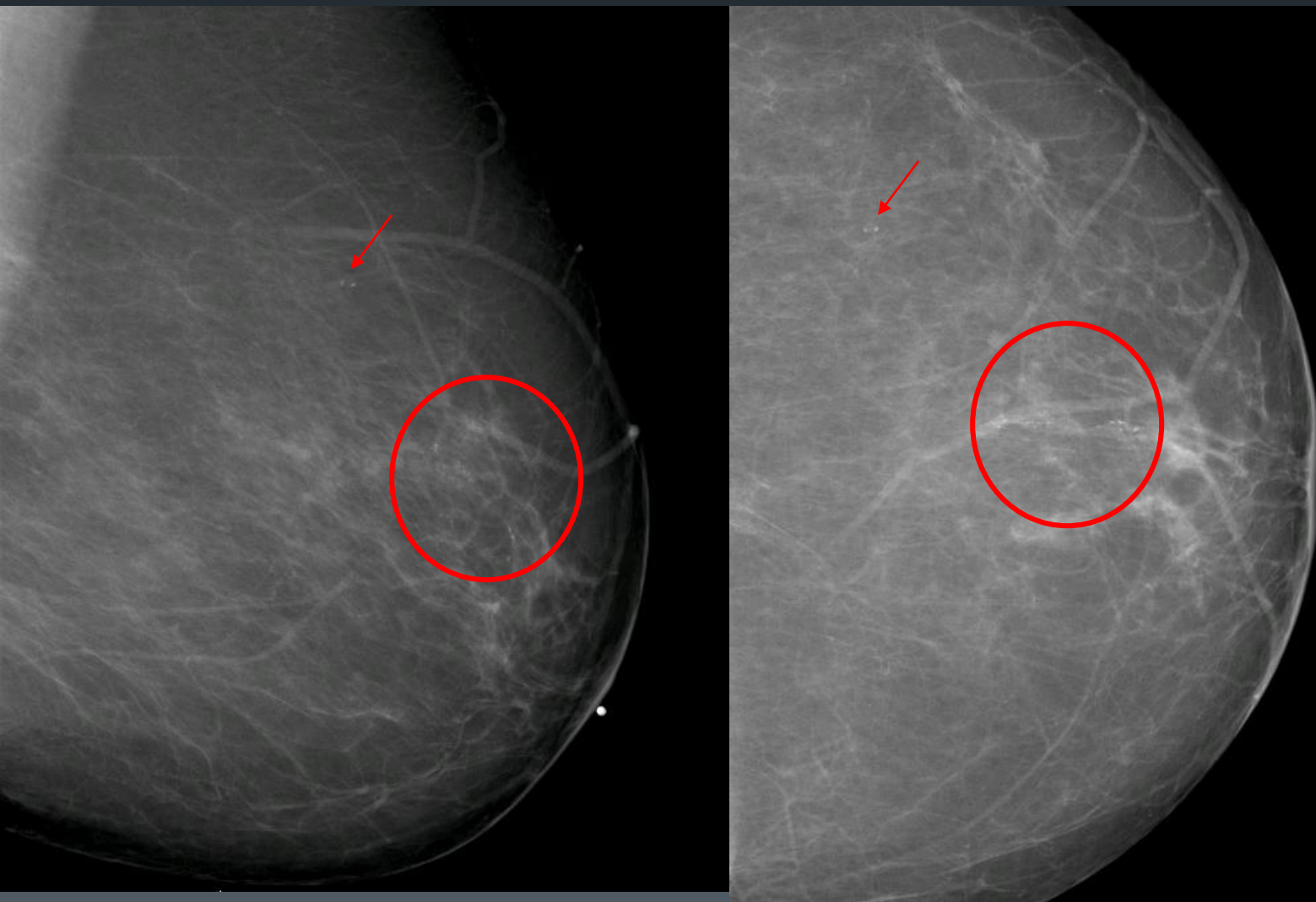
BI-RADS® Category 3 when  
there are valid clinical  
indications, or when  
short-interval imaging  
follow-up would be difficult or  
unreasonable

Images seen only or more conspicuously on mammography

- suspicious calcifications;
- unidentified masses in breast ultrasound;
- asymmetric areas;
- architectural distortions.

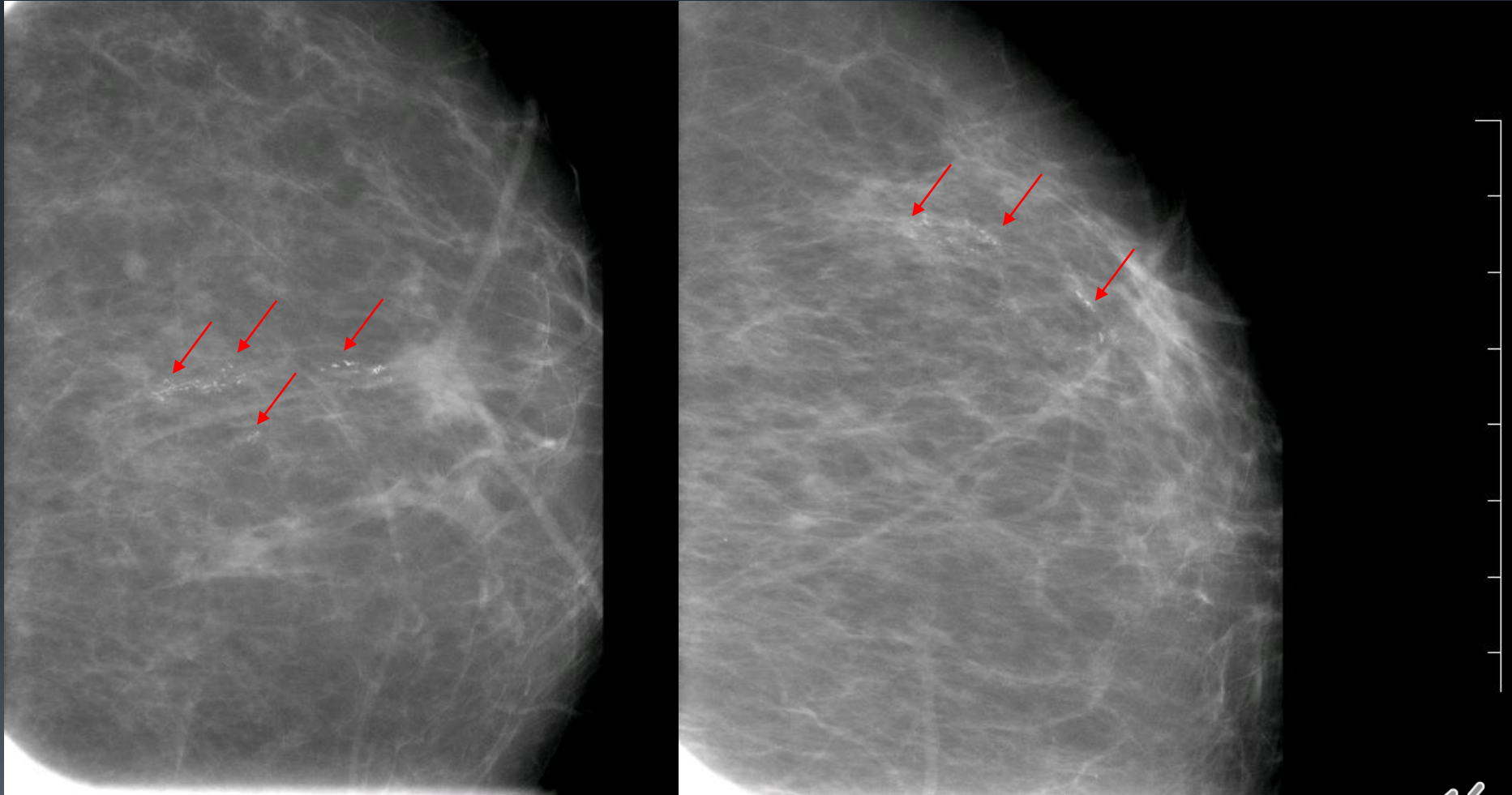


65 y.o for routine screening mammogram

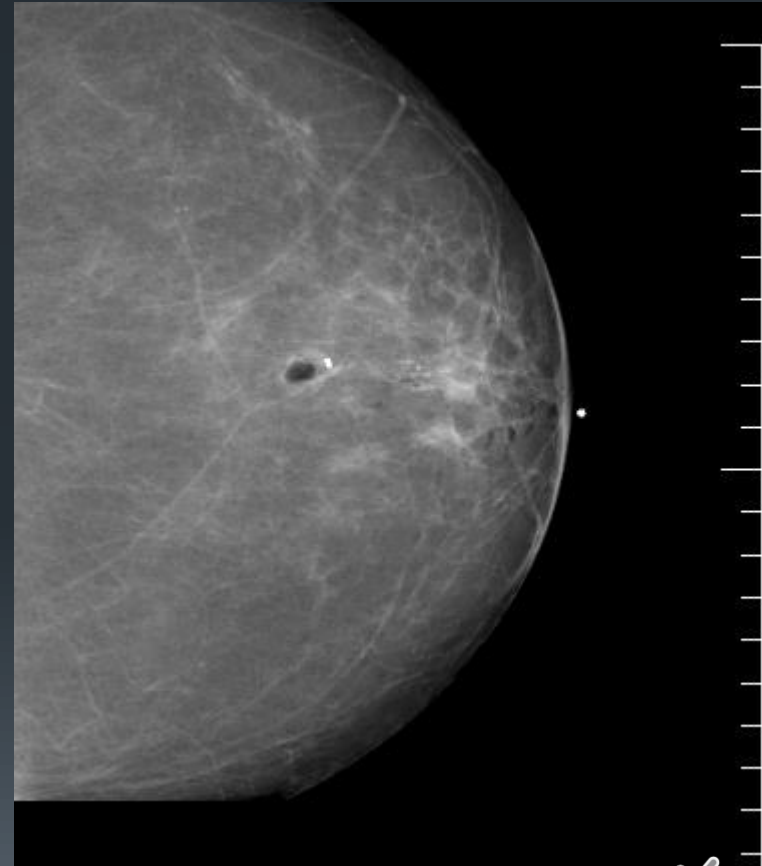
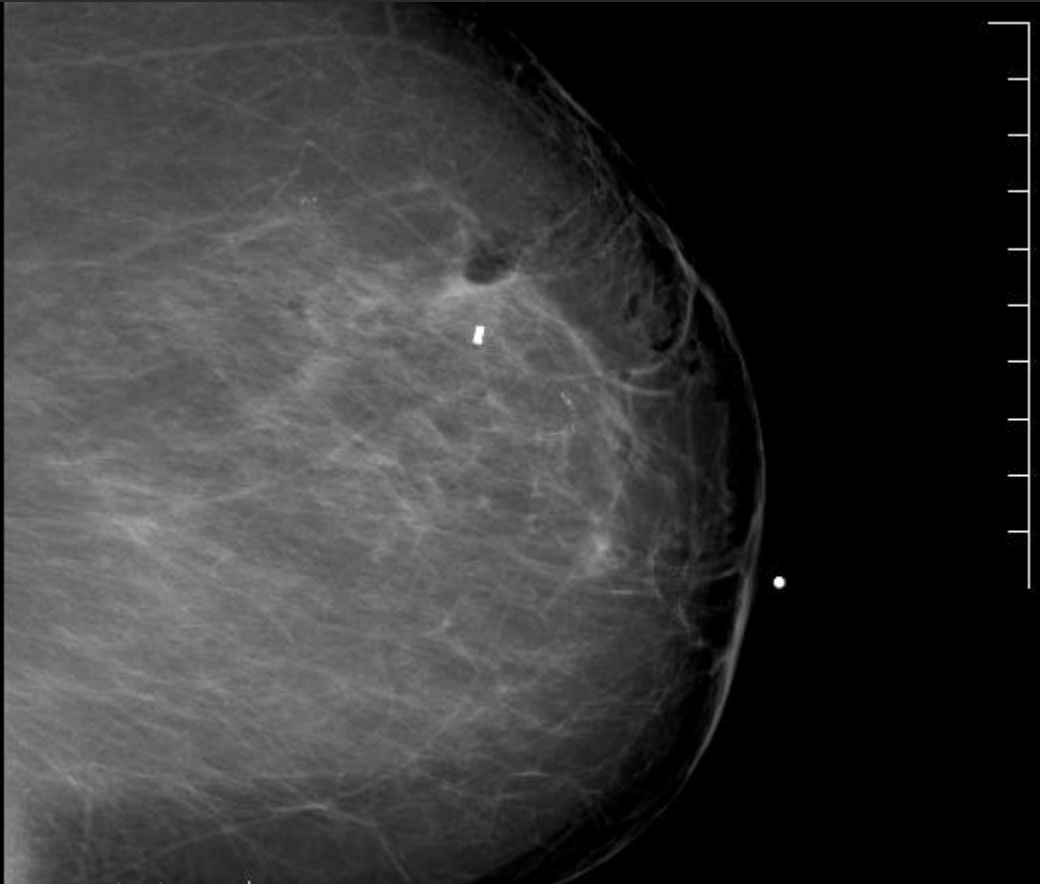


# Additional Diagnostic Work up

Left 12:00, segmental pleomorphic ca



## Stereotactic biopsy with clip placement



R

TR 4.388  
TE 2.068  
ETL 1  
FA 10.0  
Matrix 0/320/320/0Zd  
www/wlAge 0031 F  
ACC# 6912027

49.0 mm (2D)

MIP  
Series# 109  
Image# 1/1  
11/6/2006  
14:14:14

12.5 mm (2D)

R

TR 4.388  
TE 2.068

# Our approach for each case

- Extent of the disease: MRI = MG
- Lymph node status
- Status of Contralateral breast
- How was the breast parenchyma on MG?

Is the pathology concordant with the imaging findings?

DCIS high grade



# Trivia time!

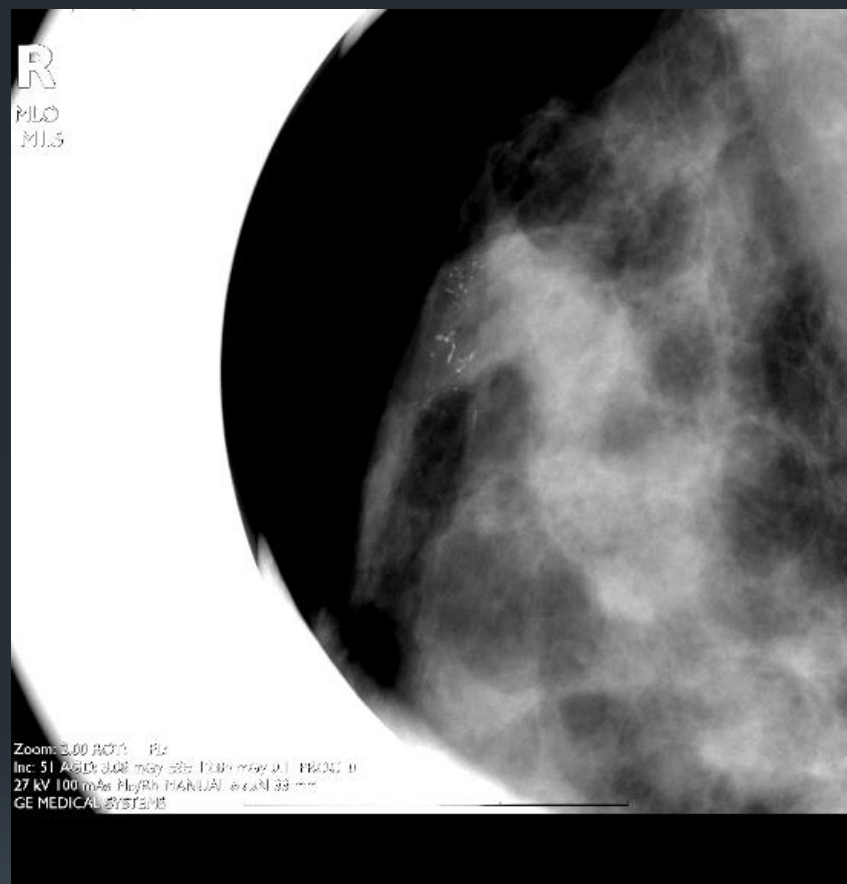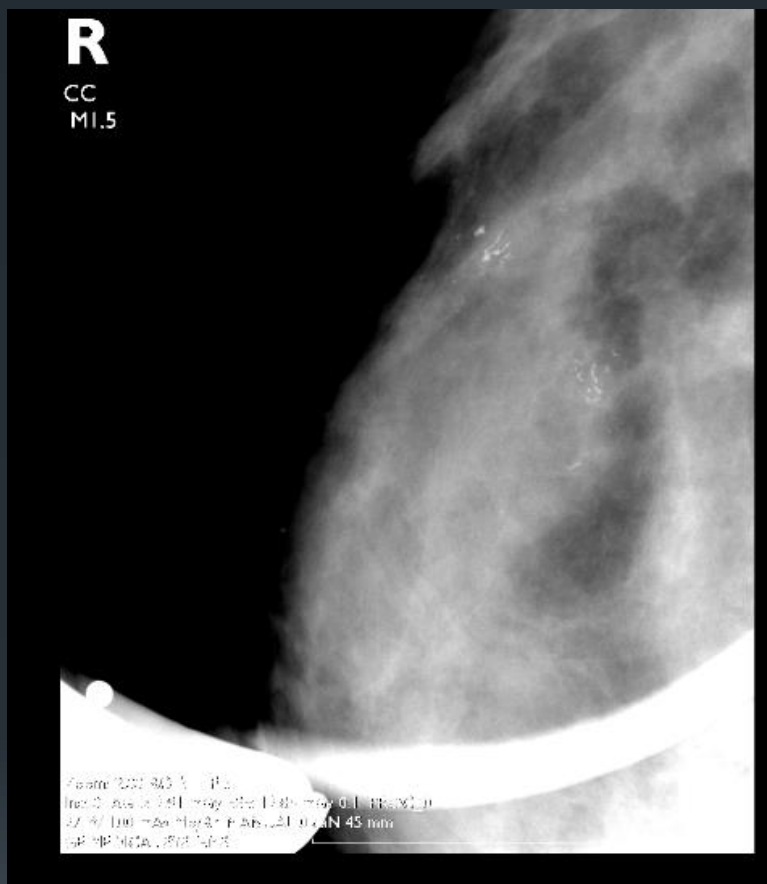
Lake Michigan and chicago river (north)



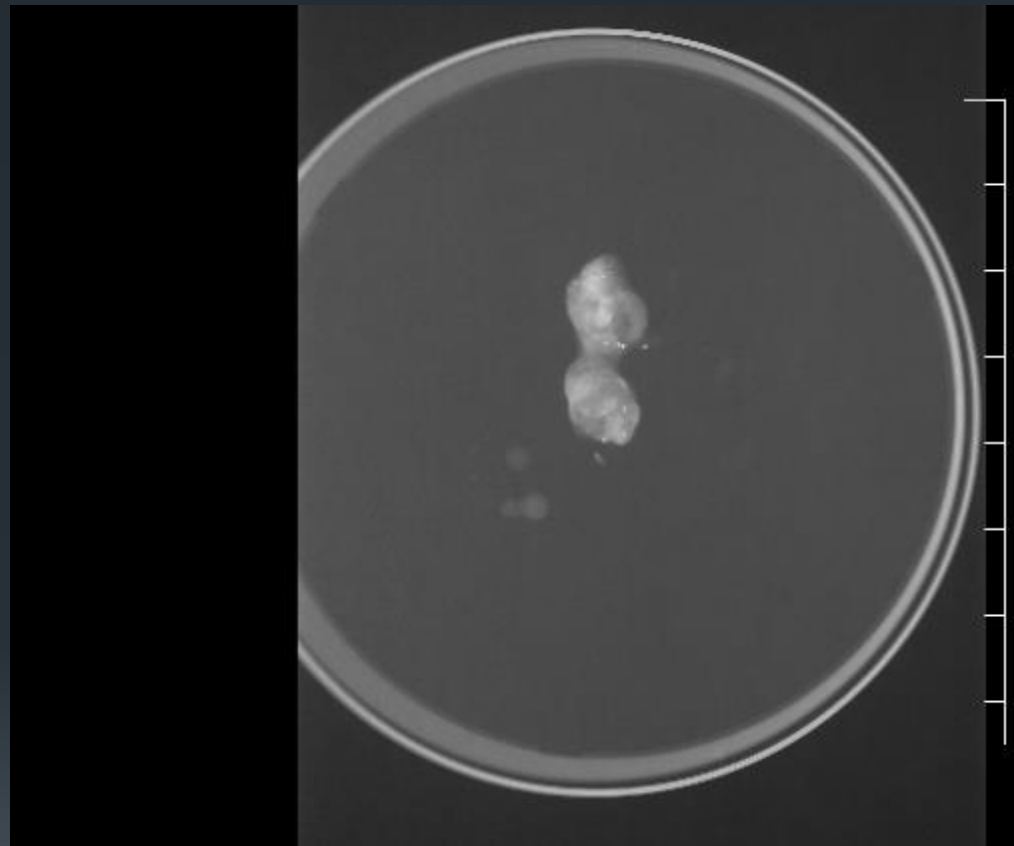Chicago river (South)

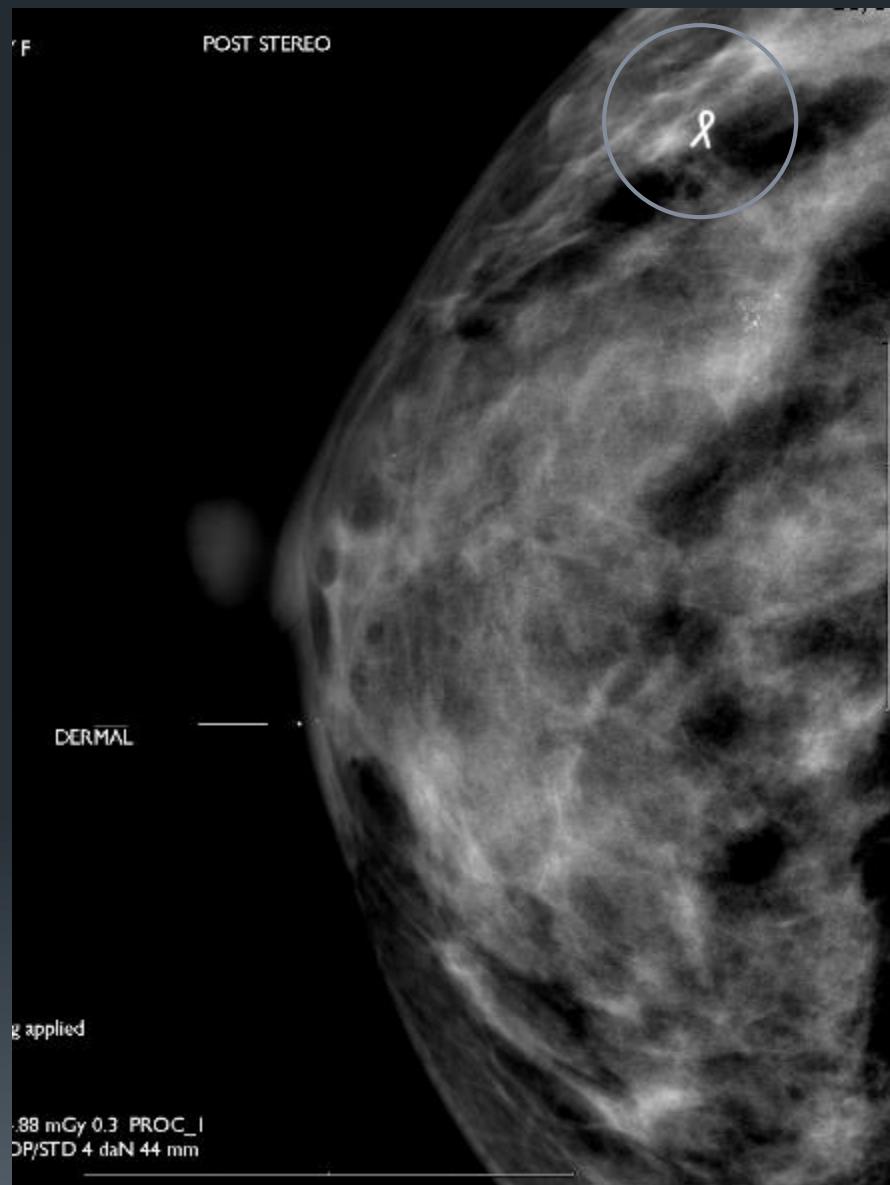


## Screen detected calcifications in 45 year old female

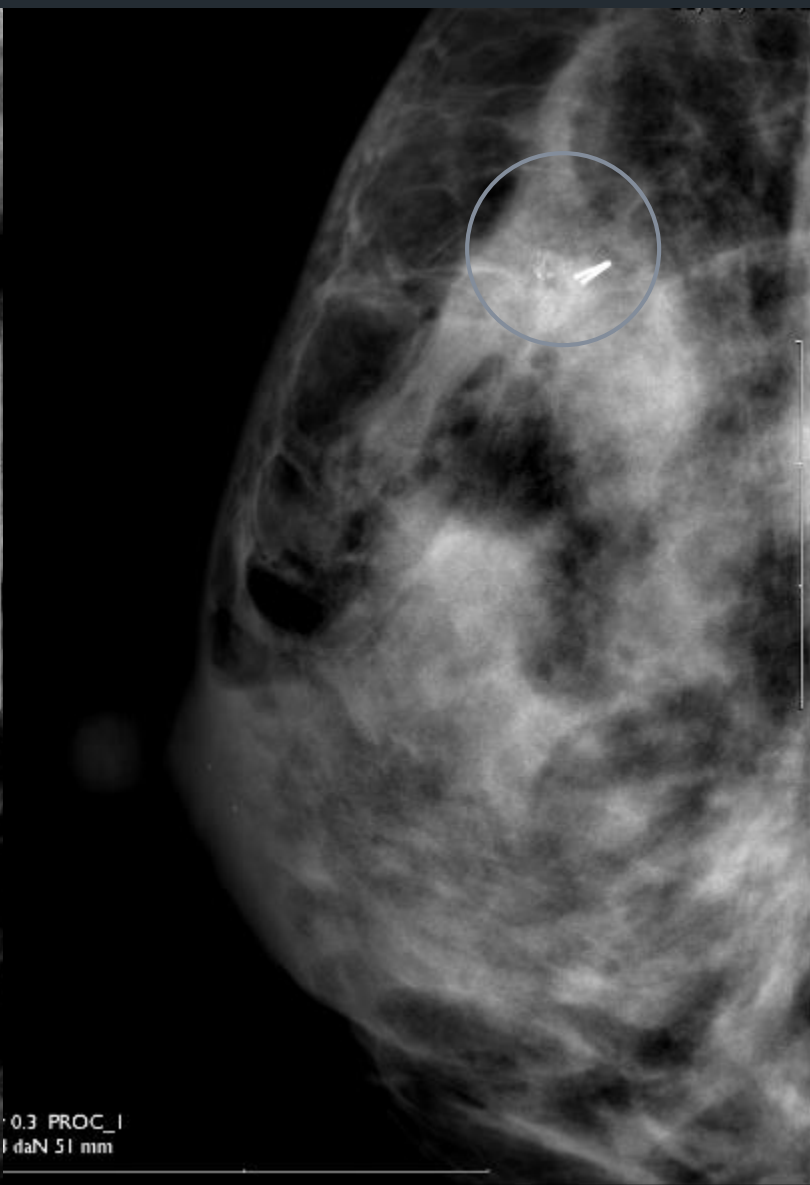


Spot Mag RCC and RMLO





R ML



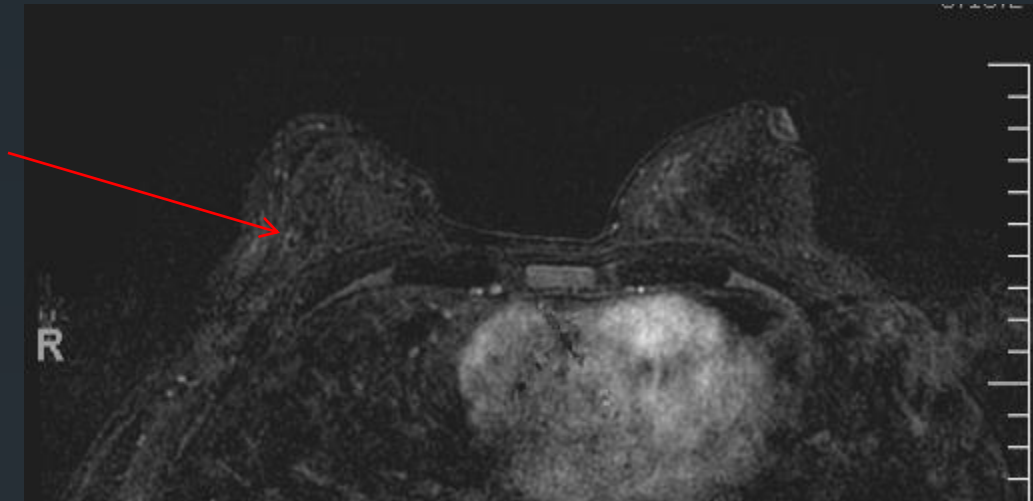
R CC



THE UNIVERSITY OF  
CHICAGO

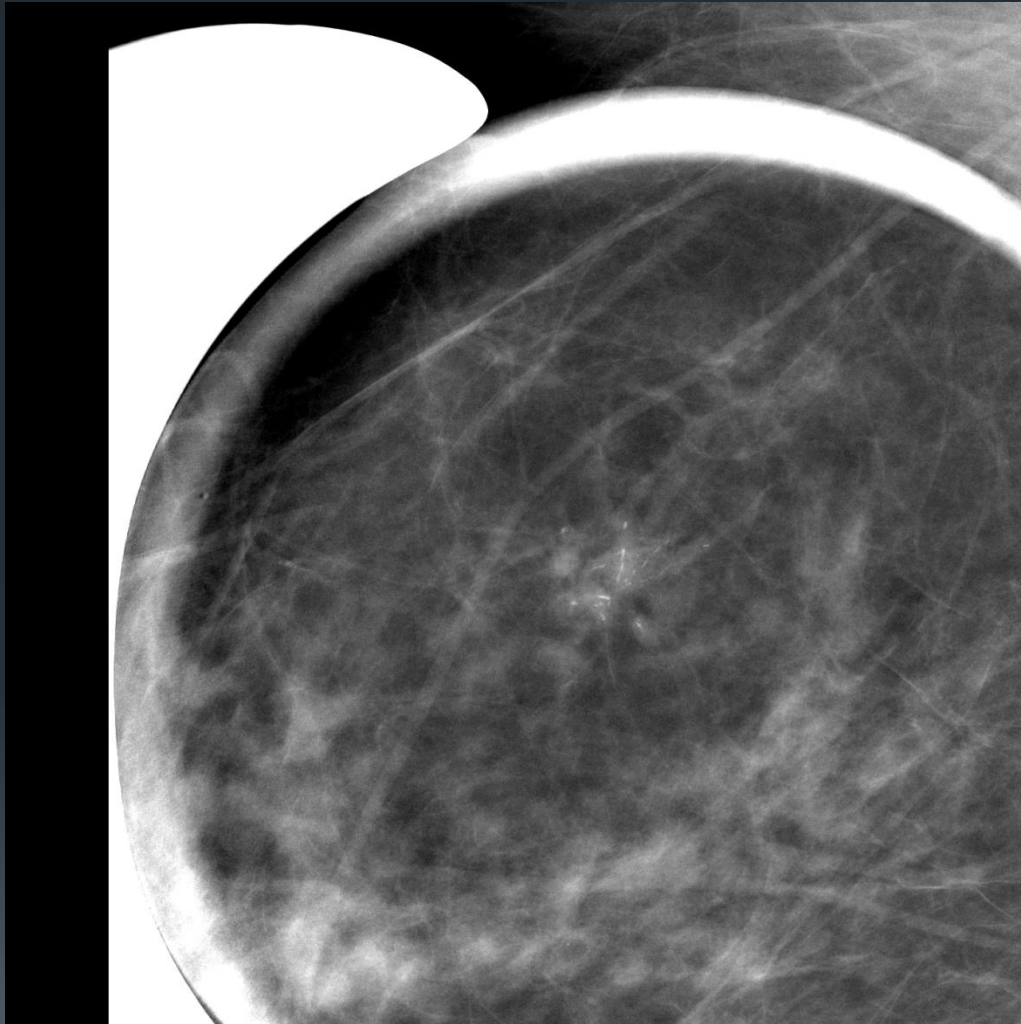


No abnormal enhancement on MRI, bilateral parenchymal enhancement seen



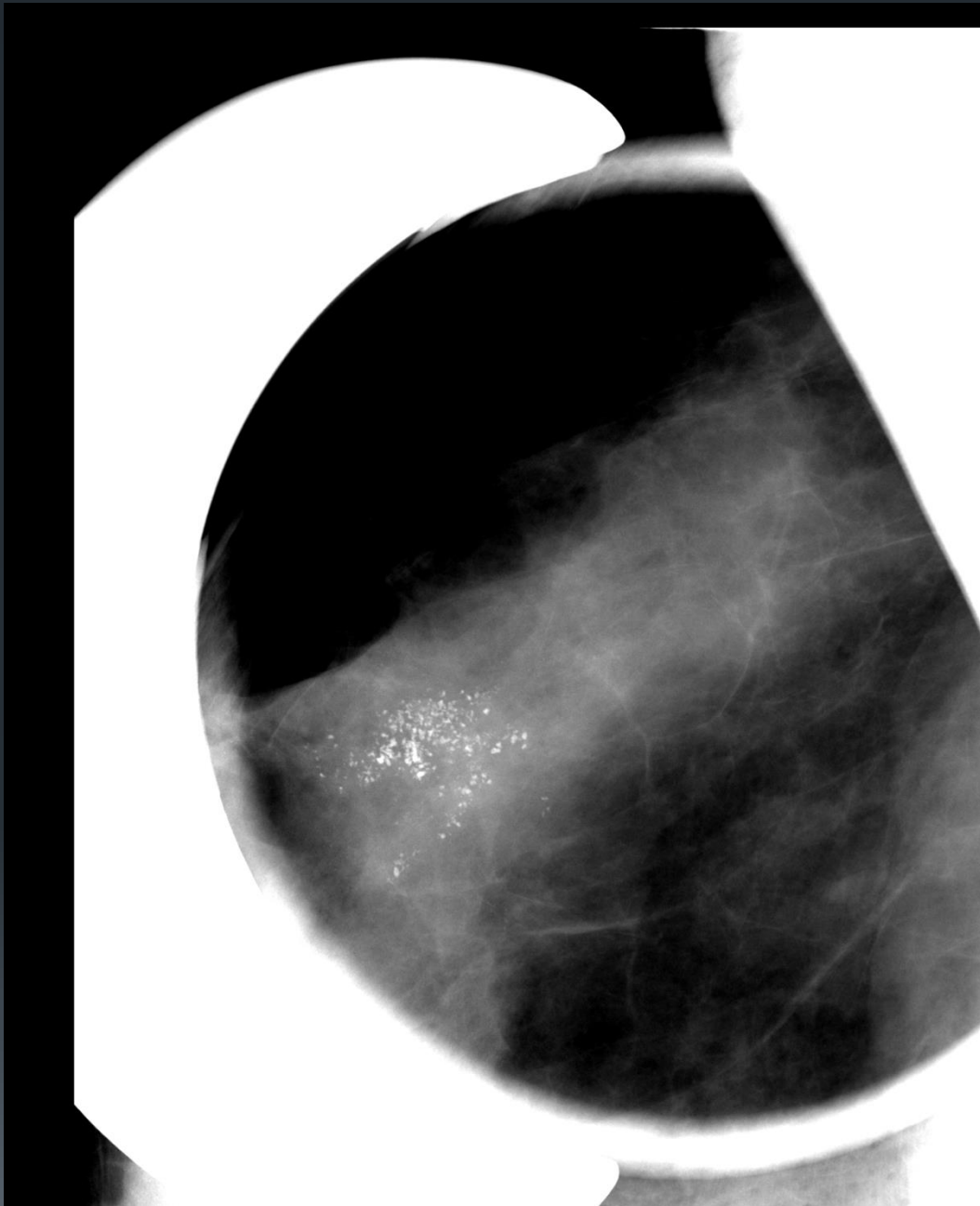
Extent of the disease: MRI < MG  
Lymph node status  
Status of Contralateral breast  
How was the breast parenchyma on MG?  
DCIS high grade: concordant!





(a) Describe the calcifications  
(b) Birads?

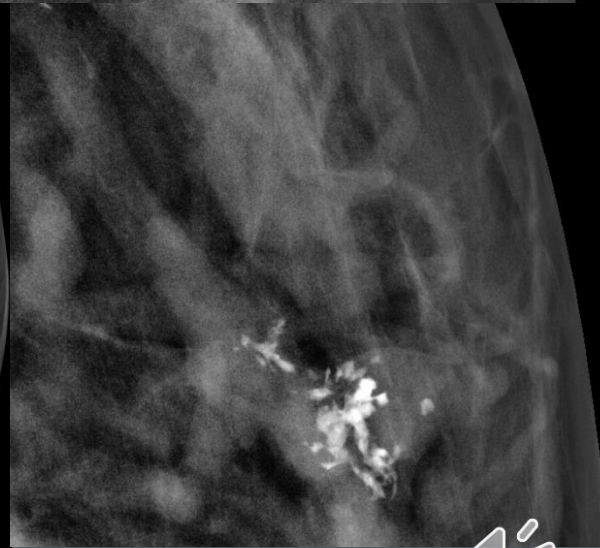
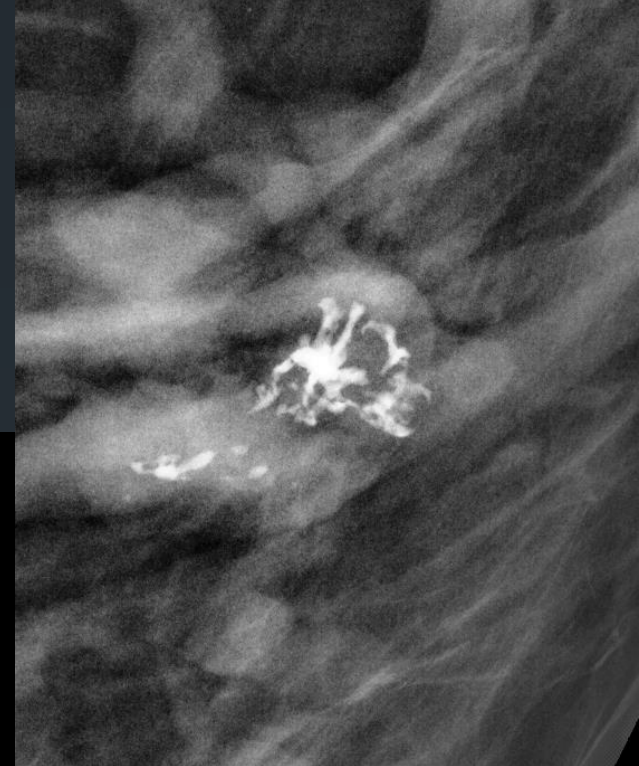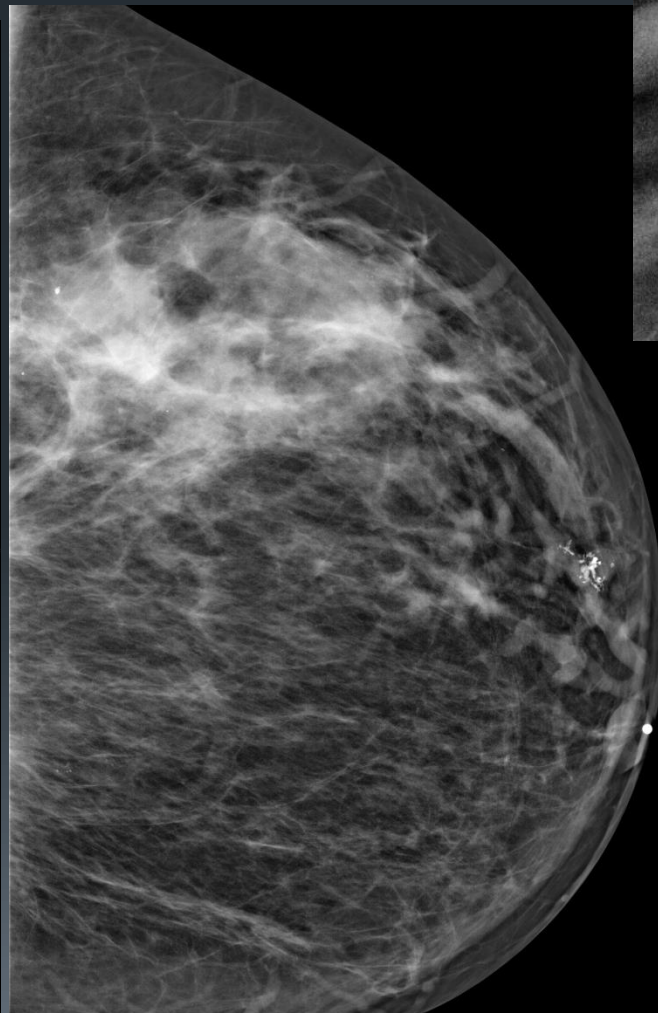
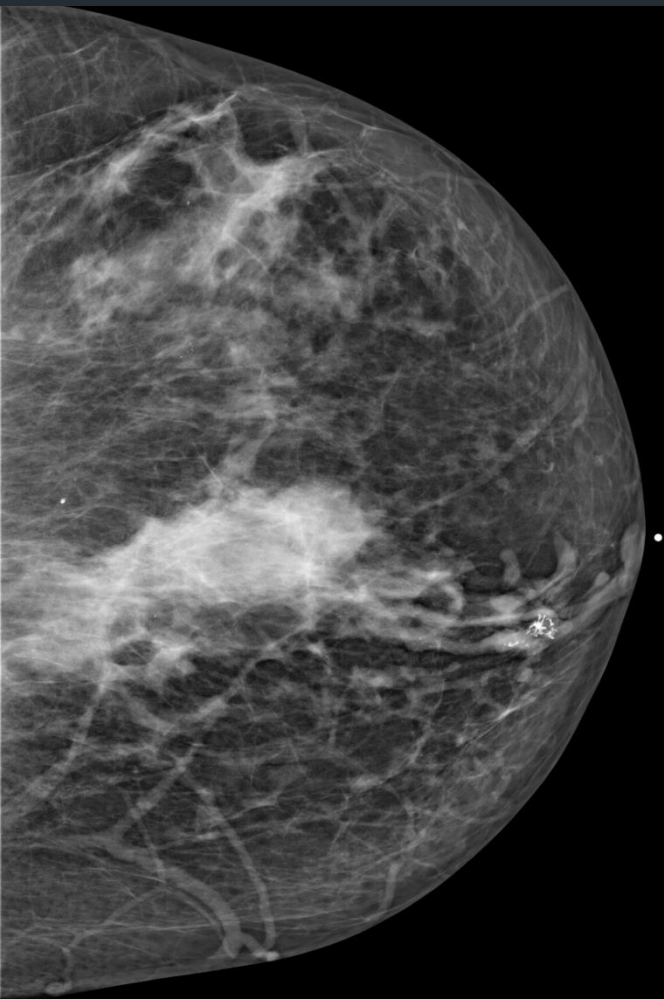


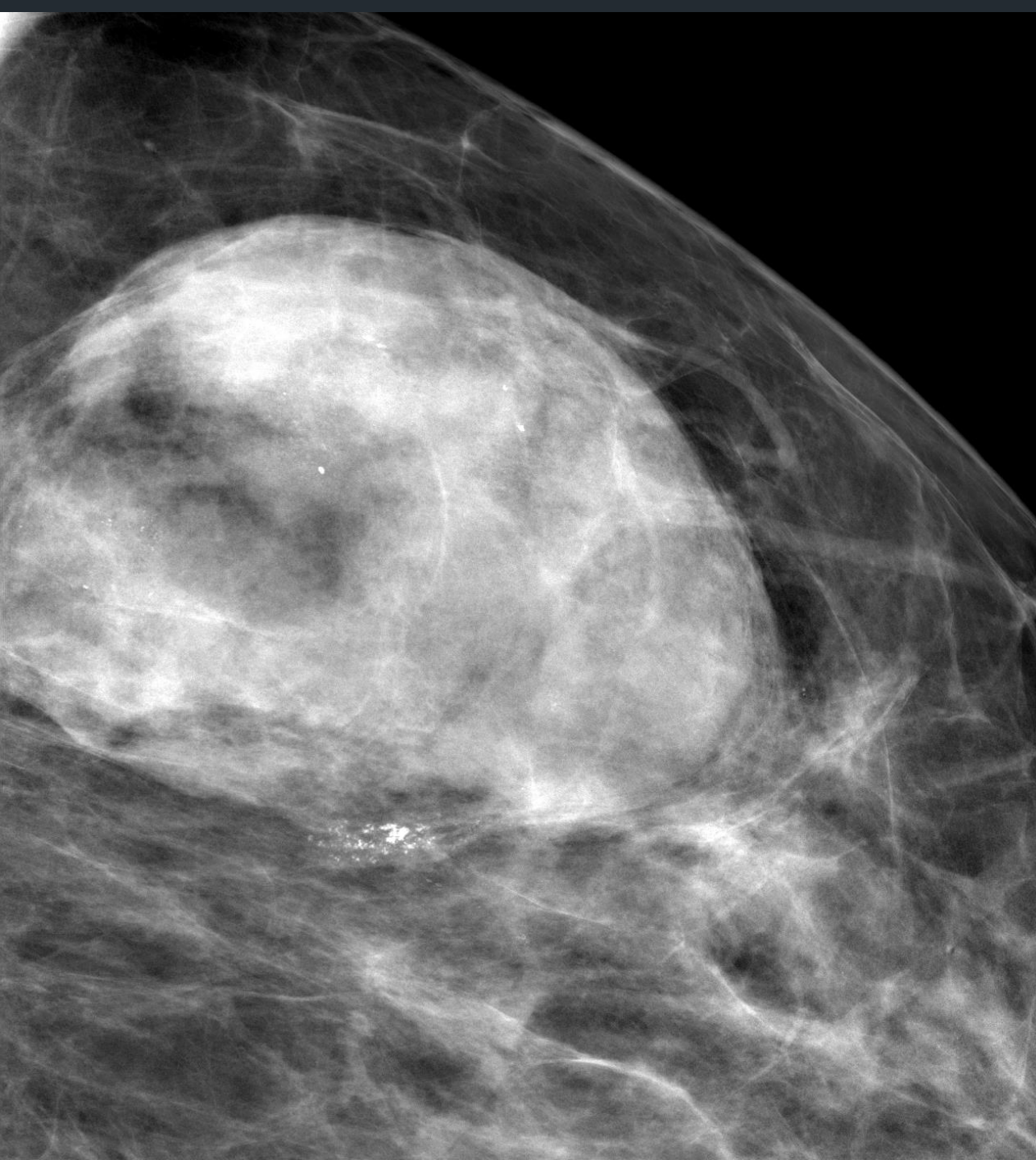


- (a) Describe the calcifications
- (b) Birads?



(a) Will you biopsy these calcifications?



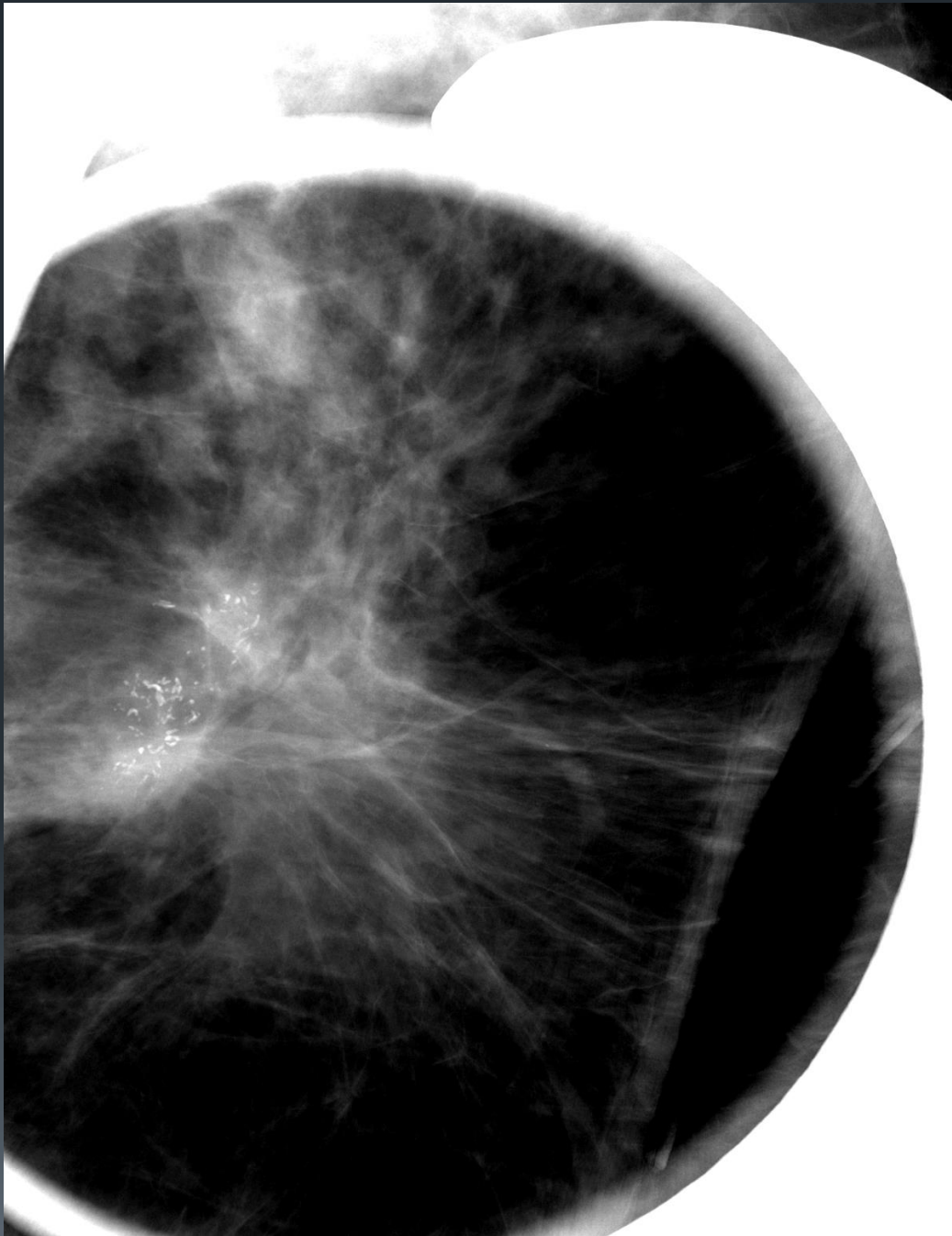


40 year old, spot  
magnification view:



THE UNIVERSITY OF  
CHICAGO

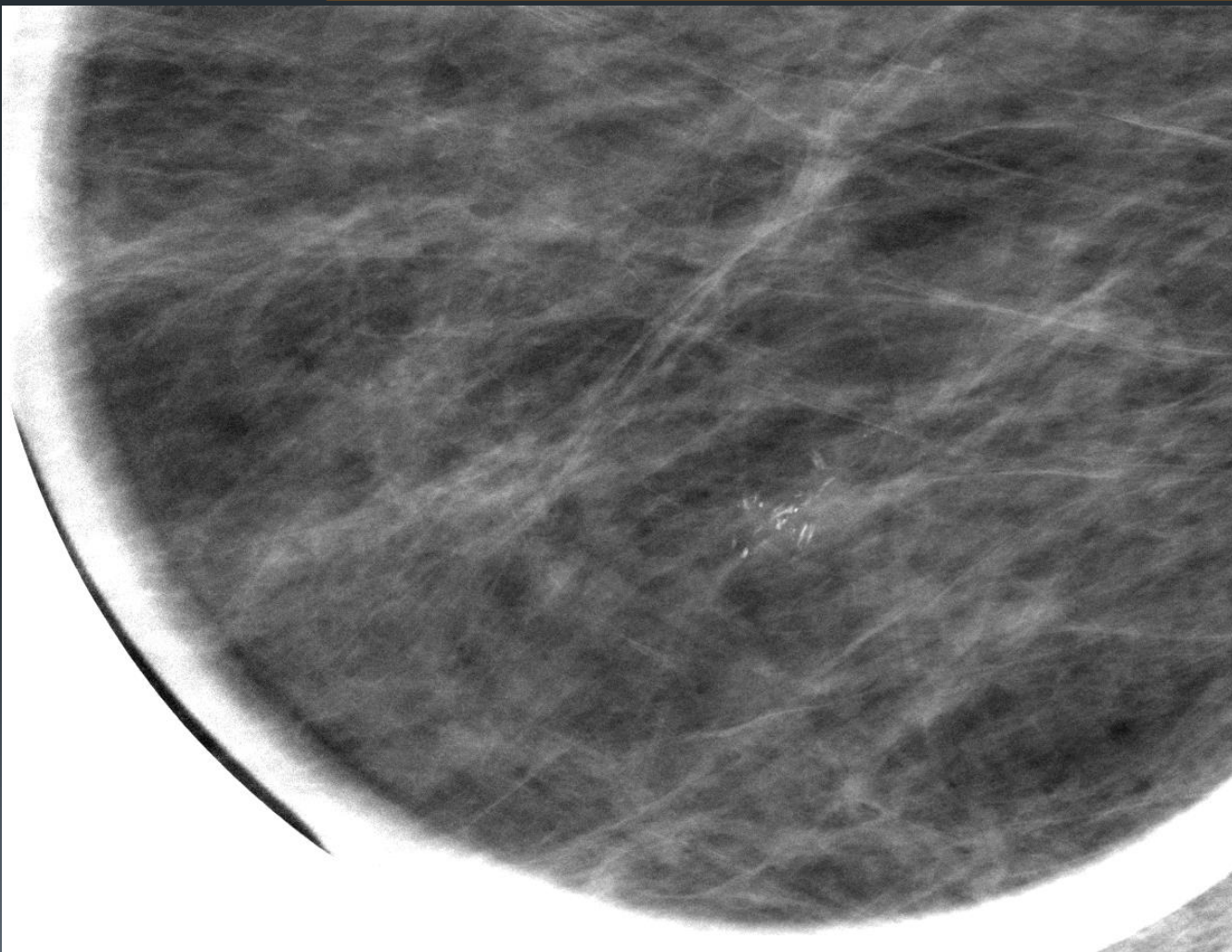


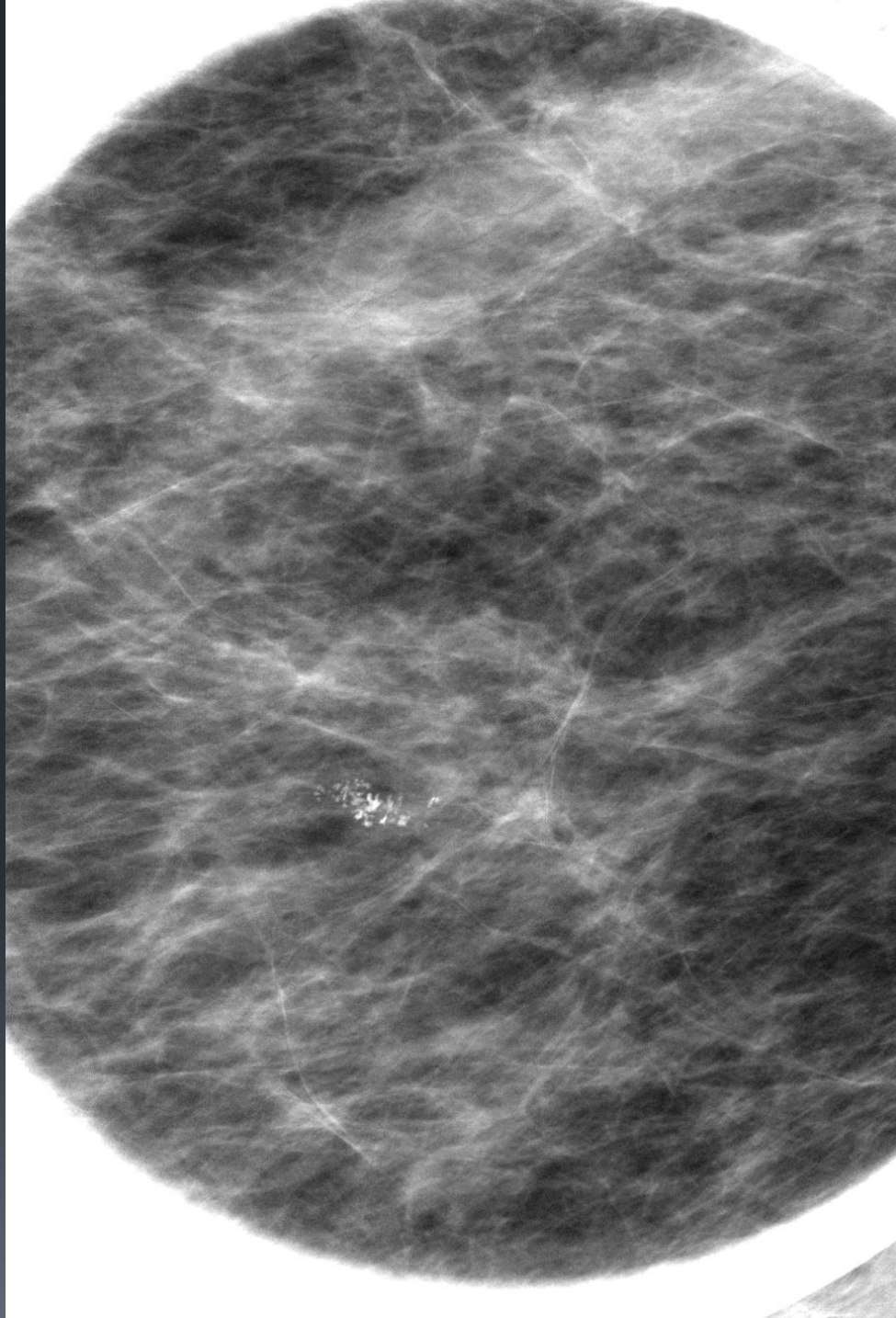


46 yo with h/o left lumpectomy  
for breast cancer  
What BIRADS?

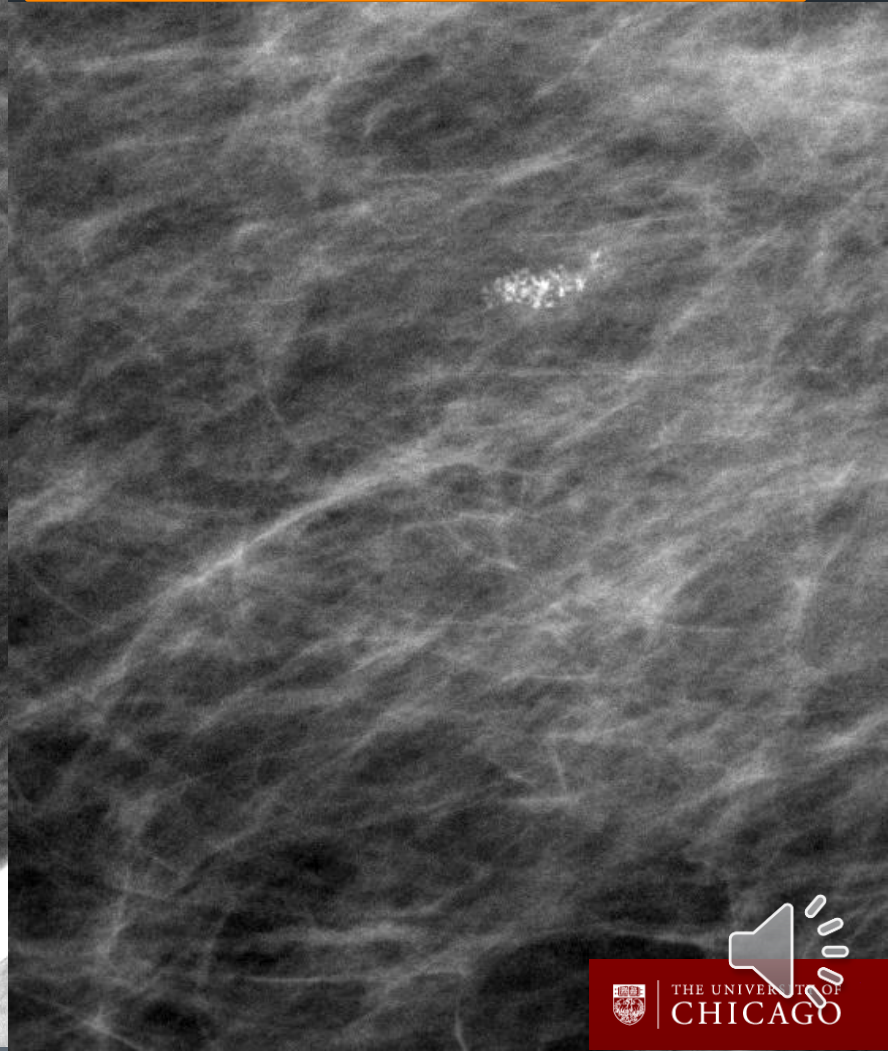

- (a) Describe the calcifications
- (b) Birads? Level of suspicion (low/ medium/ high)



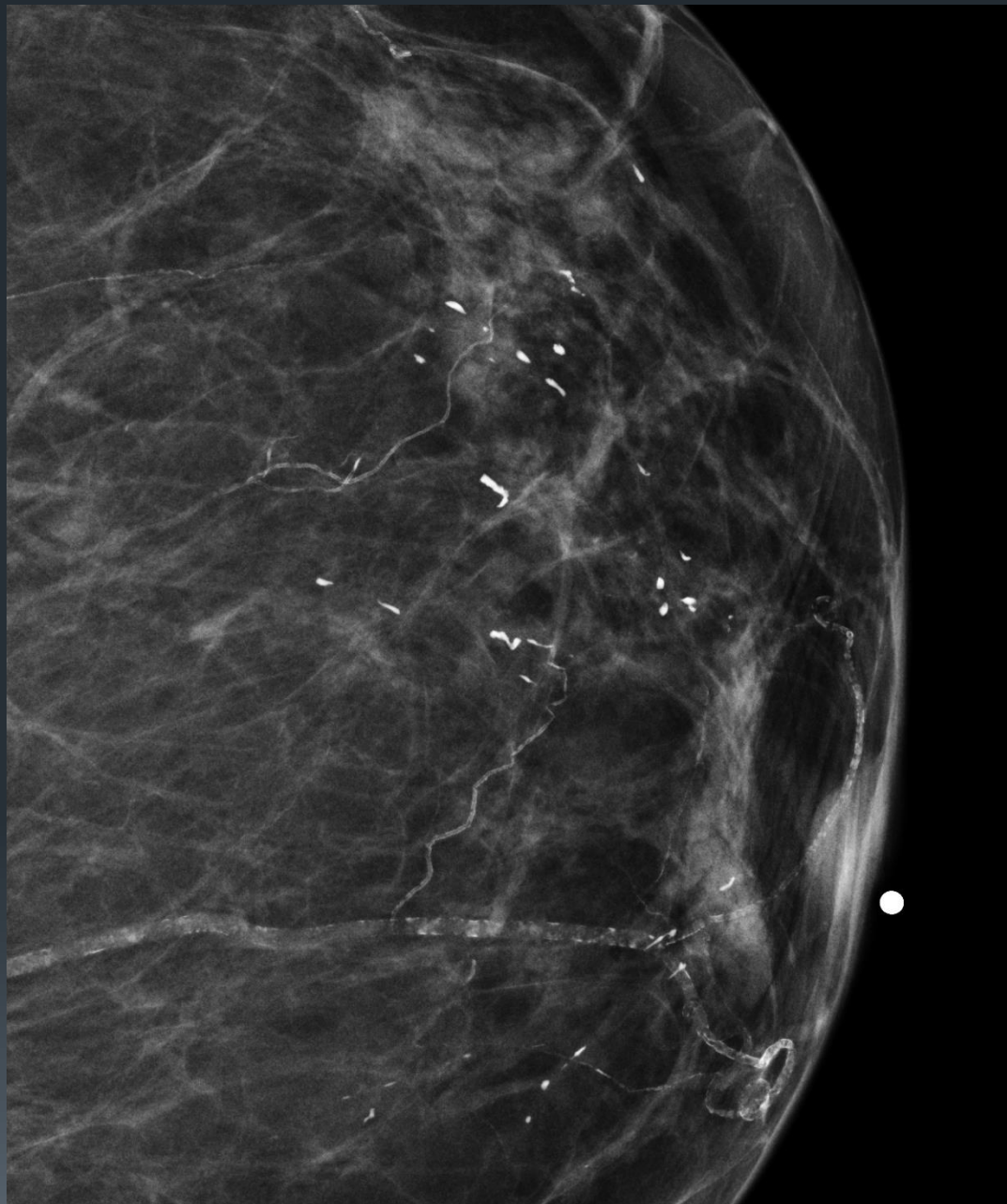


(a) Would you biopsy these calcs?



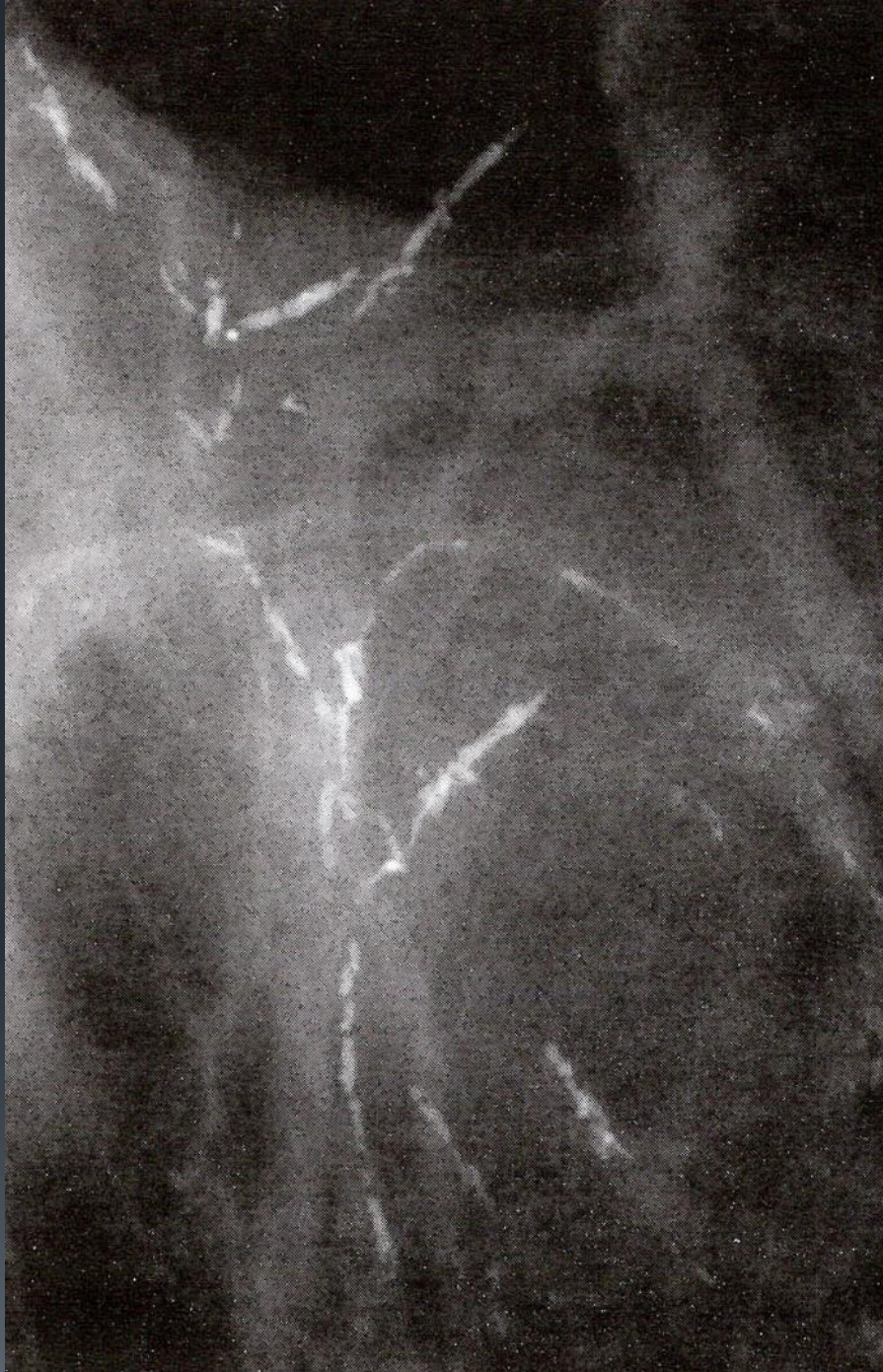THE UNIVERSITY OF  
CHICAGO





- (a) Describe the calcifications
- (b) Birads?

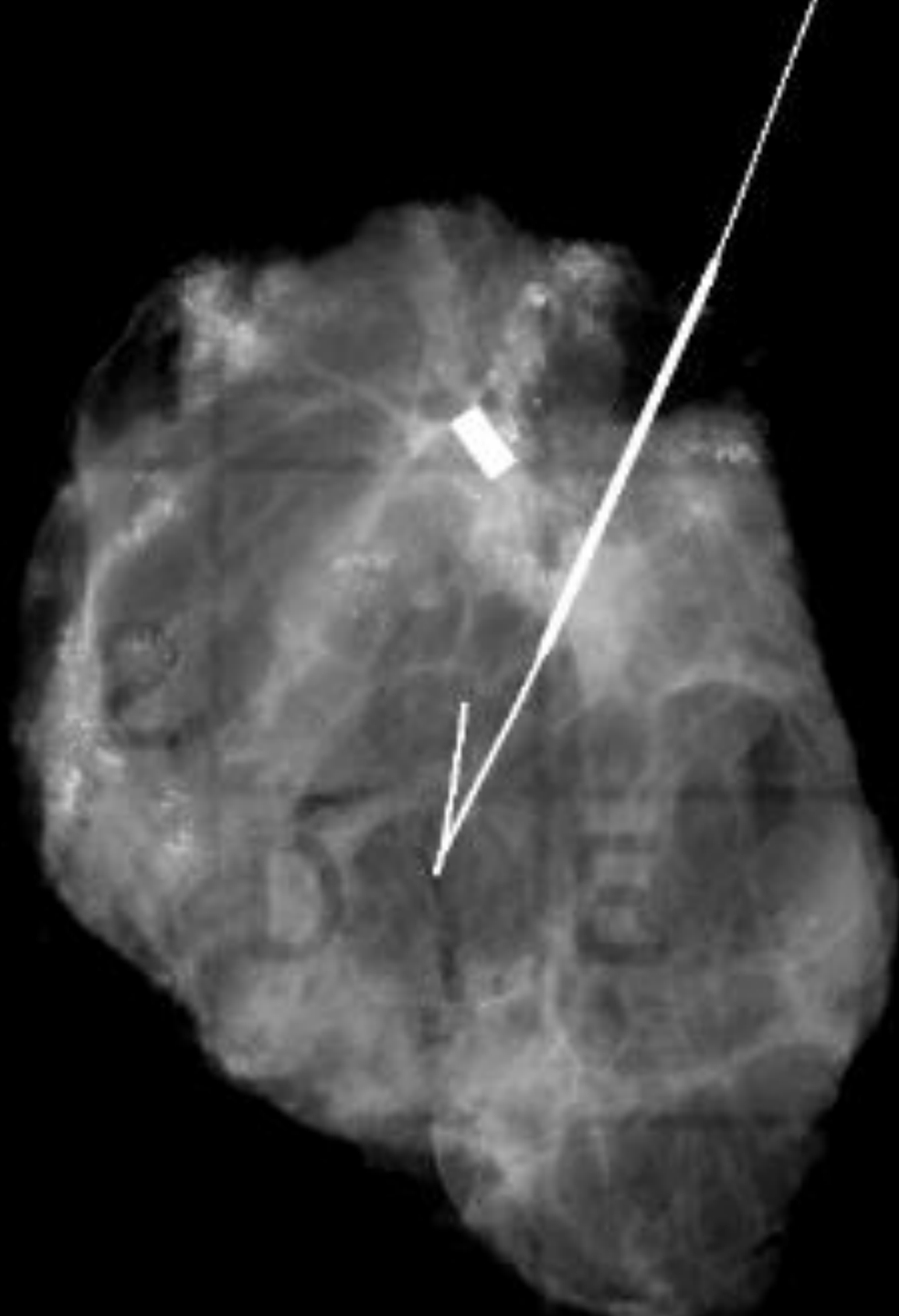



(a) Describe the calcifications

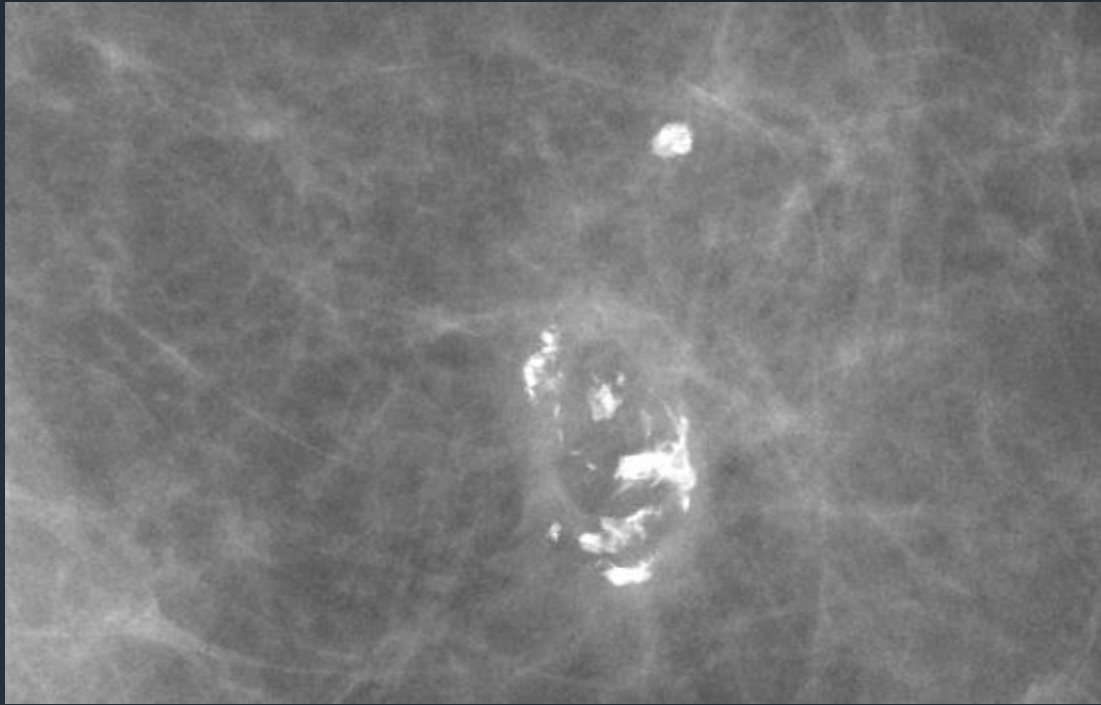
(b) What percentage of cases will demonstrate DCIS on biopsy?



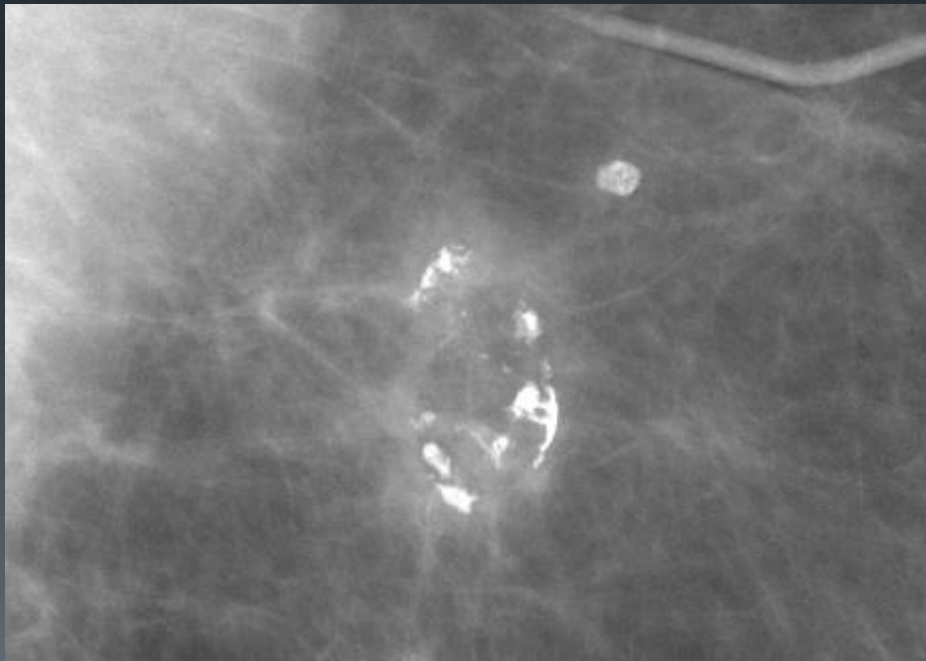


- (a) What is this procedure?
- (b) Is the specimen magnified?
- (c) What is your recommendation to the surgeon?

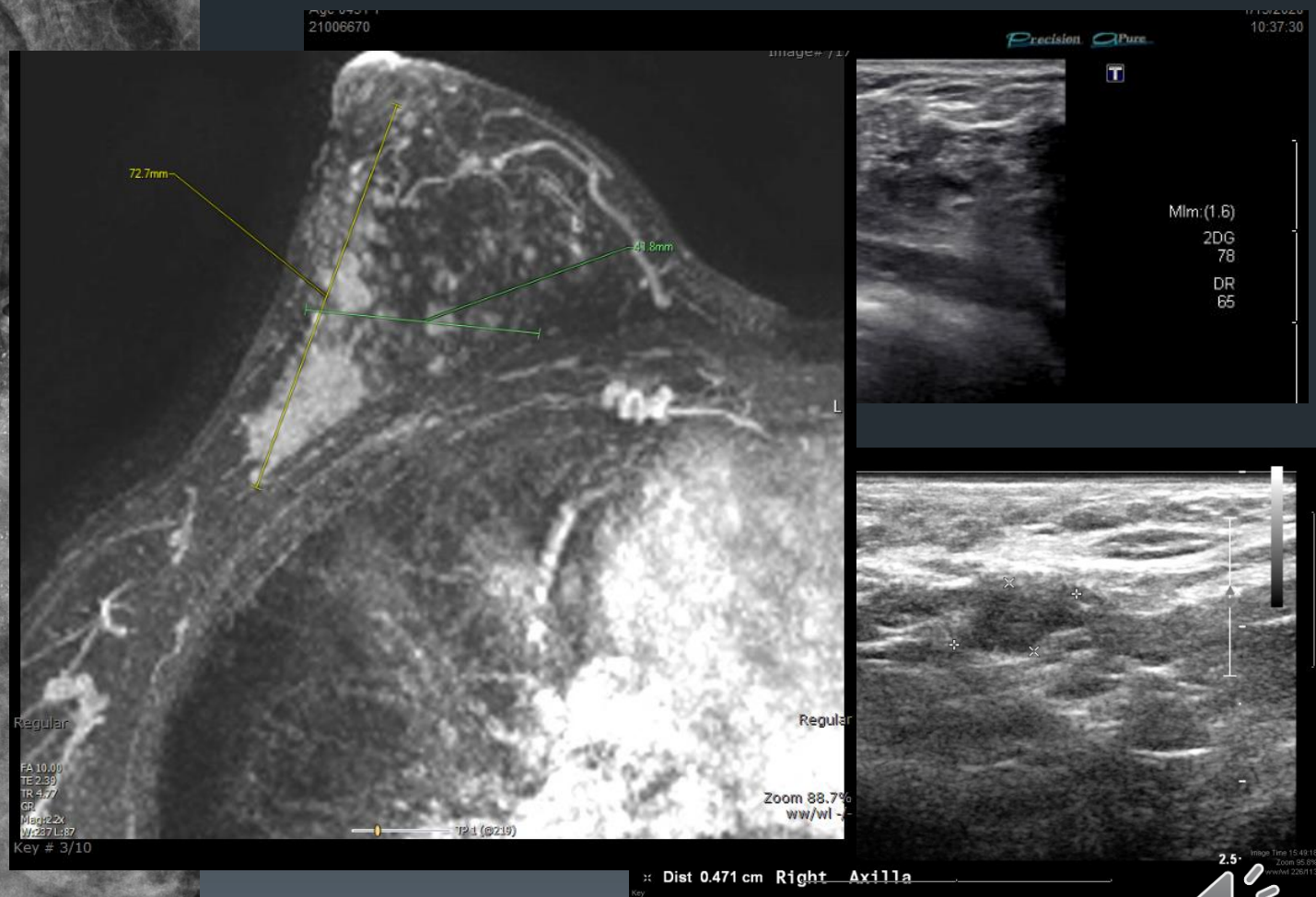




- (a) Describe the calcifications
- (b) Birads?




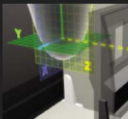



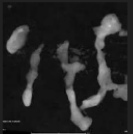
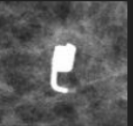



## 55 year old with palpable mass (diagnostic setting)




# Procedure

## STEP BY STEP

- 1 Introduction and explanation of the procedure 
- 2 Registration of Free and Informed Consent 
- 3 Locate the target lesion in previous exam and decide the patient's position and the access location 
- 4 Locate target lesion (15° from the midline in the positive and negative directions) and mark the target 
- 5 Apply local anesthetic to the patient and make a small skin incision 
- 6 Obtain paired stereotaxic images before and after the fire 
- 7 Start biopsy, washing and suction 
- 8 Obtain image of collected fragments and image post-procedure 
- 9 Post-procedure clip placement and image acquisition to check possible displacement 
- 10 Compressive curative, cold compress and orientations 

# Trivia time!



superhero

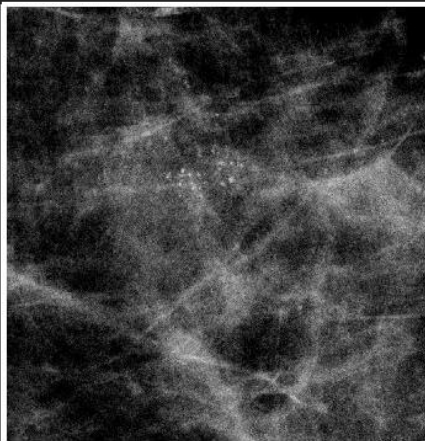


# Tomo guided Bx

## Planning the approach

### Teaching Point

The direction of approach should take the **shortest** path from the target lesion to the skin surface.

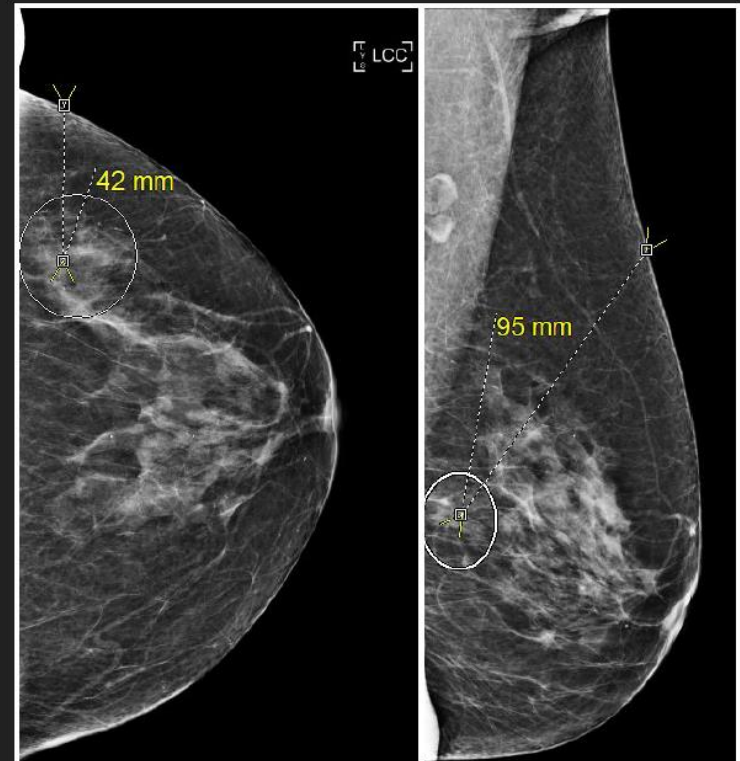


Microcalcifications recommended for biopsy.

On the ML view measure the distance from the target to the **superior** skin surface.

On the CC view measure the distance from the target to the **lateral** or **medial** skin surface.

The compression paddles are placed in the plane of approach at the time of biopsy.

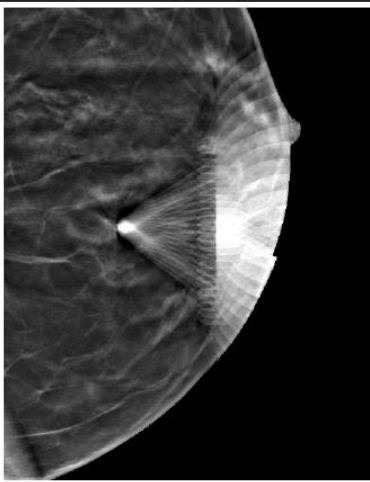
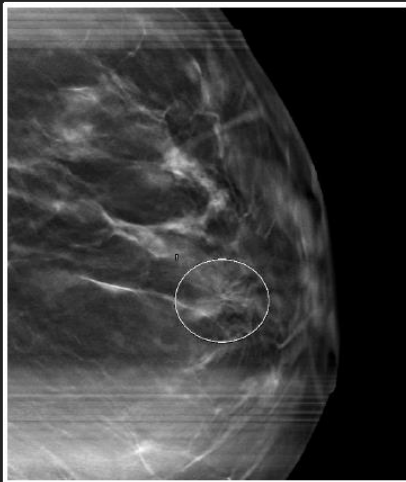


CC (left) and ML (right) views. The microcalcifications are closest to the lateral skin surface. A **lateral** approach was taken. The left breast was placed in **LM compression** at the time of biopsy.



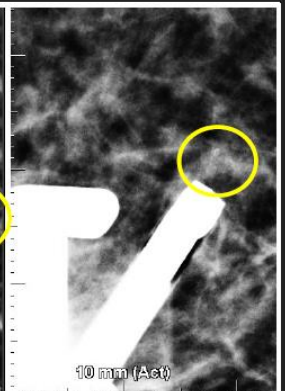
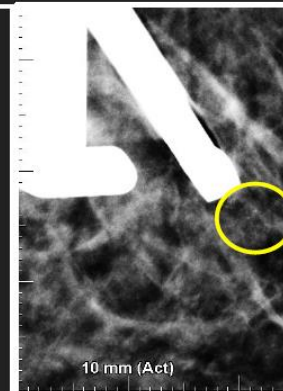
# Tomo guided Bx

## Prefire images



Appropriately positioned needle tip at an **architectural distortion** prior to firing. This lesion was occult on standard mammographic views. (Left)

DBT is ideal to confirm correct prefire positioning for **non-calcified lesions** without mammographic correlate.



Stereotactic pair images demonstrate microcalcifications distal to an appropriately positioned needle tip.


### Pitfall

Needle artifact can potentially **obscure** subtle microcalcifications on DBT.

After needle advancement, the position of the needle tip is confirmed with additional exposures.

Both **15 degree stereotactic pair images** or **digital breast tomosynthesis** images can be obtained depending on the lesion and radiologist preference.

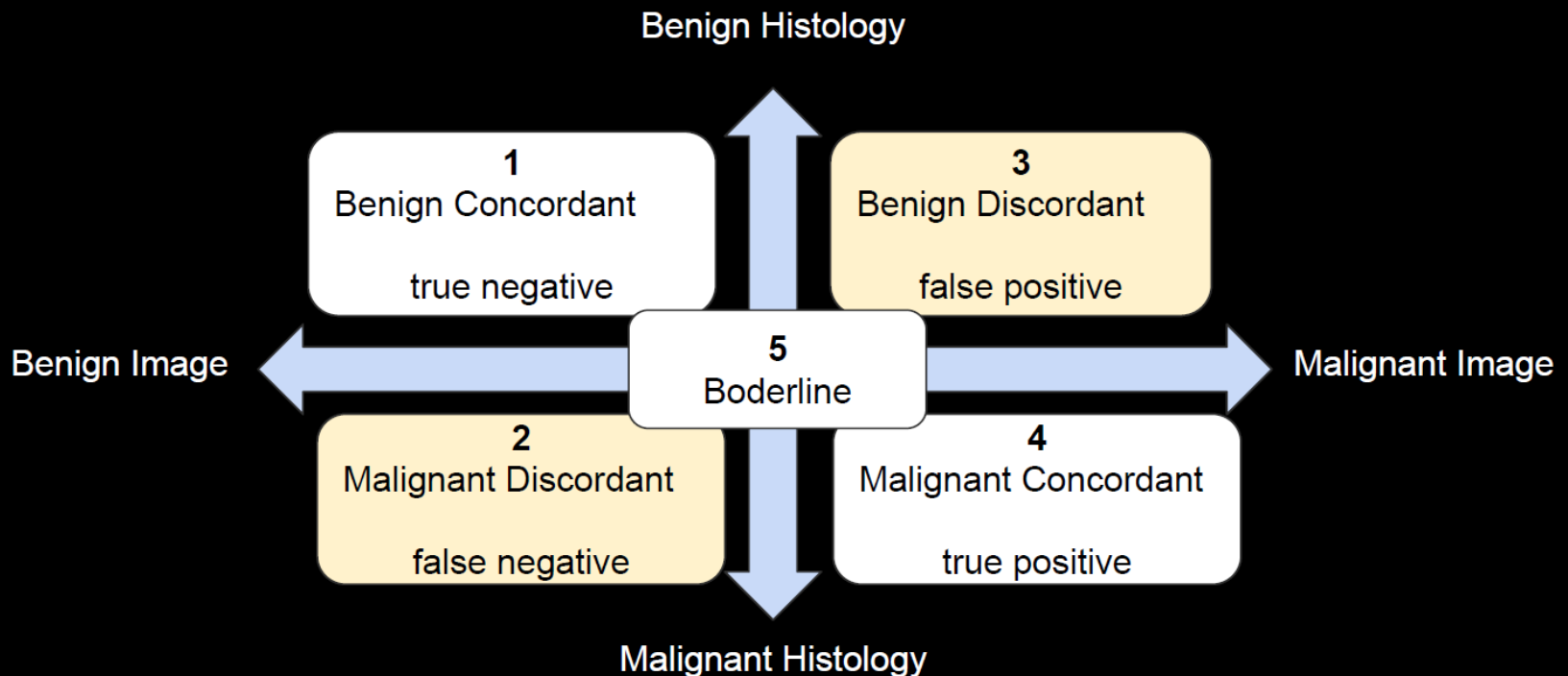
Depress the **green** button to **fire** the needle once the needle is appropriately positioned.



# Is this concordant?

## RADIOLOGIC-PATHOLOGIC CORRELATION

BI-RADS® CATEGORY:



# Wire Localization: Eligibility Criteria

Eligibility criteria at our institution

- Unifocal cancer measuring less than 2 cm: one wire is indicated.
- Unifocal cancer measuring greater than 2 cm: two or more wires are used to bracket the lesion.
- Status post neoadjuvant chemotherapy.
- Axillary lymph node with surgical clip in place.
- Excisional biopsy of suspicious calcifications, path proven premalignant conditions, or atypical papilloma.



# Wire Localization: Benefits

- Established standard of care.
- No radiation to the patient.
- Less ancillary personnel required for implementation.
- More easily retrieved.
- Can be repositioned.
- Easier to bracket the lesion with a wire.
- Can place multiple wires for synchronous or large lesions without concern for increased radiation.



# Wire Localization: Technique

- Rad must have reviewed the films to:

- Ensure that lesion can be localized
- Ensure that the surgeon and RAD are on the same page
- Plan/approach takes into account the entire lesion/s
- Shortest distance possible
- Determine appropriate needle length
- May need repeat images on the day of (e.g hematoma)



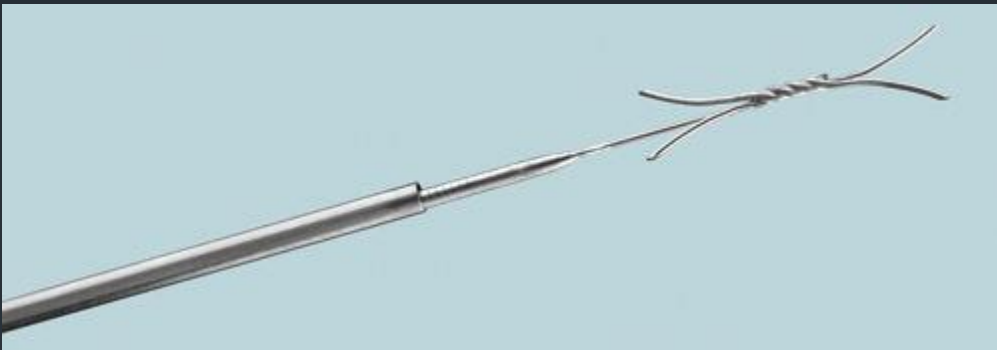
# Wire Localization: Drawbacks

- Must be placed same day as surgery—restricts the schedule of both the radiologist and the surgeons.
- Inconvenient/uncomfortable for patient. Vasovagal reactions reported in 7.4-20%
- Increased subjective pain reporting, likely exacerbated by visible external portion of the wire.
- Wires must be placed 1 cm beyond the lesion to ensure it is adequately transfixed with the reinforced portion of the wire traversing the lesion.
- Increased rate of positive tumor margins requiring re-excision/mastectomy when multiple wires are used.
- Negative margins in 70.8%-87.4%
- Negative margins in prospective and RCT studies comparing wire locs to other methods: 42.3%-94.5%

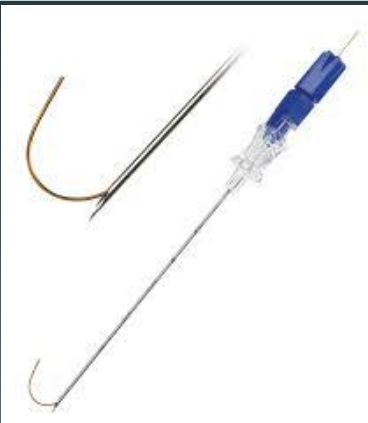



Kopans



J wire



X-Reidy wire

# Radioactive Seed Localization: Eligibility Criteria and Exclusions

- Eligibility criteria at our institution:
  - Small unifocal masses measuring up to 10-15 mm with clip.
  - Small cluster of calcifications with clip.
- Relative exclusions:
  - Biopsy clip is displaced.
  - Post-procedural hematoma or seroma that obscures the lesion.



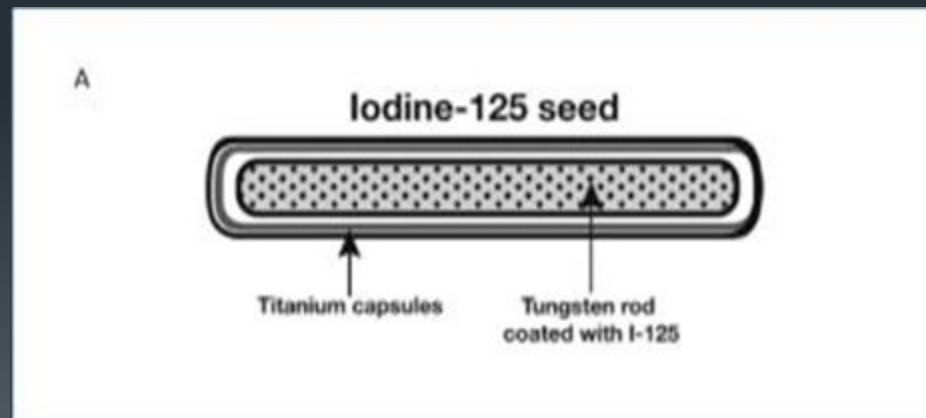
Radioactive seed with  
deployment needle  
and penny for size  
reference.

Citation needed\*\*\*



# History

- First reported in 1999 by Dauway and colleagues
- $^{125}\text{I}$  radioactive seed is calibrated upto 0.3 mCi.
- Half life is approximately 60 days with 27keV gamma radiation
- 18G needle with tip occluded by bone wax is preloaded.



# Radioactive Seed Localization: Technique

- Similar to wire localization, RSL can be performed using mammography, ultrasound, or MRI to locate the cancer.
- Once the tumor is located, a tiny, low-dose (200-300  $\mu\text{Ci}$ ) Iodine-125 radioactive seed is placed at the tumor site using an 18-g needle.
- After the seed is inserted, the patient may resume normal activities without fear of seed displacement.
- The seeds are easily located with Geiger Counter and removed from the room between 2 and 5 days post implantation.
- The seed is removed from the tissue specimen in surgery, or the tissue specimen containing the seed can be sent to pathology for removal of the seed and analysis of the tissue.
- The seed is then disposed off in accordance with the State regulations.



# Radioactive Seed Localization: Benefits

- Many surgeons are already familiar with gamma probe, secondary to their experience with sentinel node biopsy.
- More convenient for patients and surgeons—operating time and scheduling is much more flexible.
- Reportedly less painful/uncomfortable for patients.
- Equivalent surgical outcome, margins and size of resection cavity.
- More flexible surgical approach, which can lead to improved cosmesis.
- Internal to patient- less likely to be dislodged.



# Radioactive Seed Localization: Drawbacks

- Issues with radioactivity of the seed:
  - Radiation to patient: 200-300 uCi/seed of I-125.
- Cannot use more than three seeds, or under MR-guidance
- Radiation safety officer/authorized user on site
- Training of additional support staff
  - May not be conducive to smaller sites.
- Contraindicated in pregnancy or breastfeeding.
- Radiation disposal issues.
- Half-life of the seed is 59.43 days and half-life of the needle is 120 days.

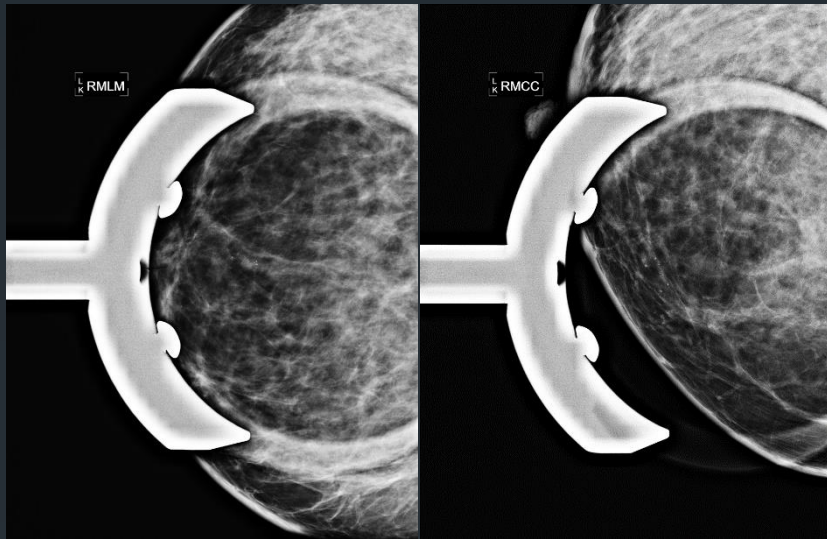


# Radioactive Seed Localization: Drawbacks (continued)

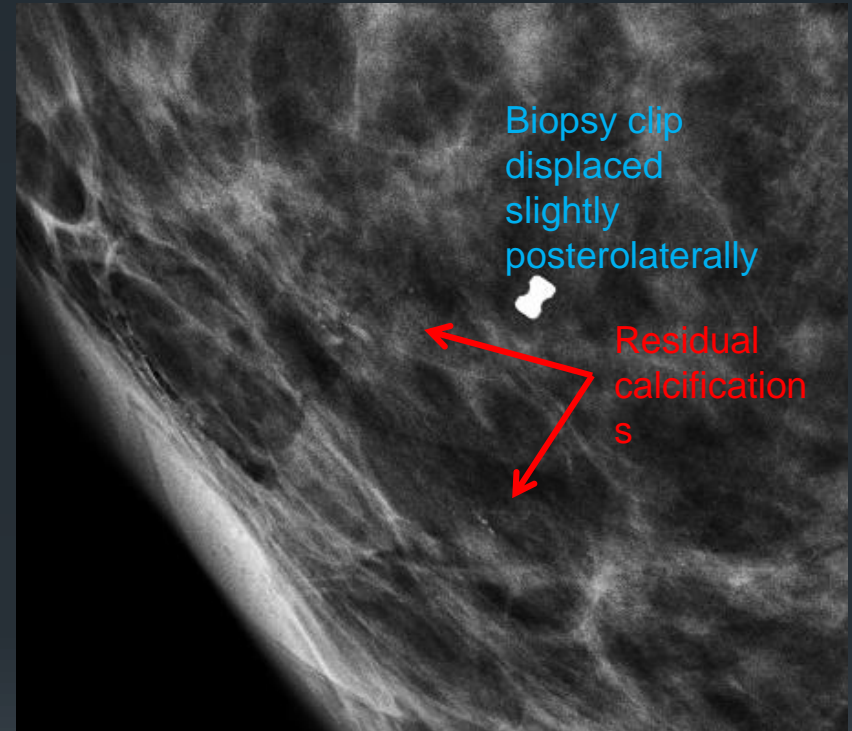
- New technique to learn for radiologists and technologists.
- If two seeds are used, can be difficult to detect and/or be misinterpreted at surgery.
- If deployed incorrectly, seed cannot be repositioned.
- If too much wax, seed can fail to deploy.
- Must do RSL before Tc-99m lymphoscintigraphy.
- Loss or non-recovery of seeds
  - Additional imaging/surgery may be needed.



# Wire Localization, Case One: Mammography



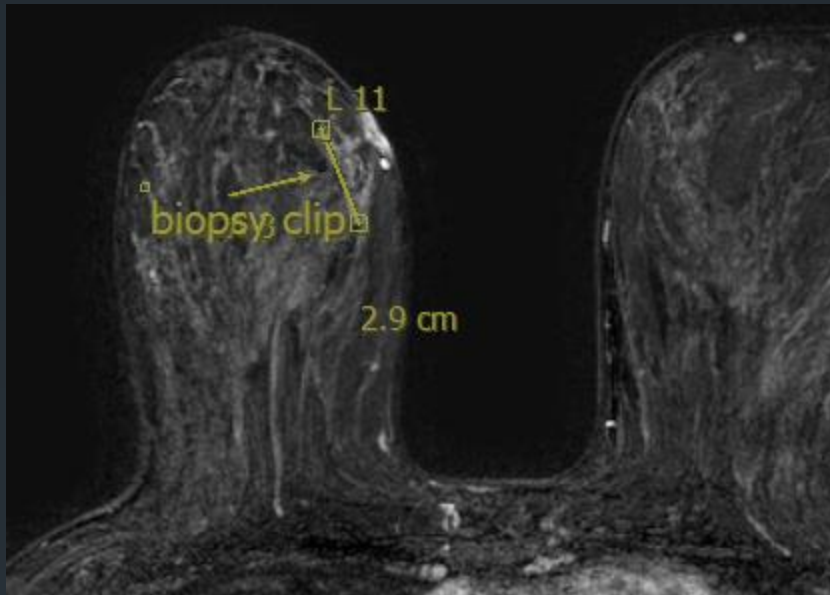
43 y/o F presented for routine screening mammography with new group of calcifications identified in the right lower inner breast. Diagnostic spot magnification views (above) show linear branching pattern, spanning 3cm.



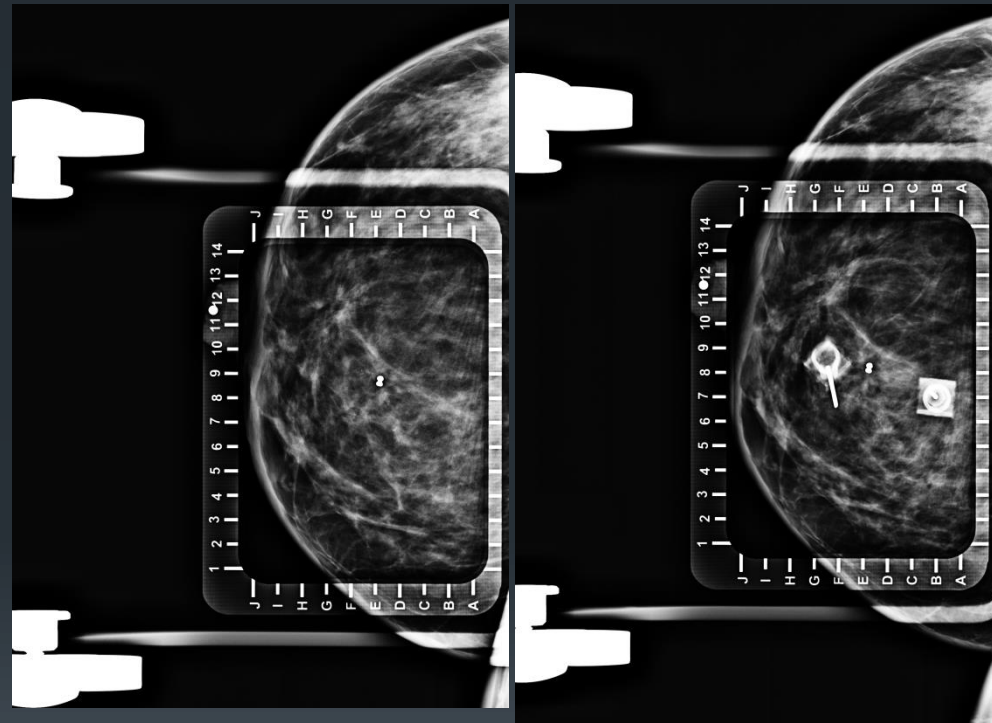
Biopsy confirmed DCIS. The clip is displaced slightly posterior and lateral to the residual calcifications. Localization using bracketing wires is recommended for calcifications spanning  $\geq 2$ cm.



# Wire Localization



Preoperative MRI confirms unifocal disease. Non mass enhancement spans 2.9 cm, and correlates with location of residual calcifications on mammography. Biopsy clip is again identified slightly posterior and lateral to the calcifications.

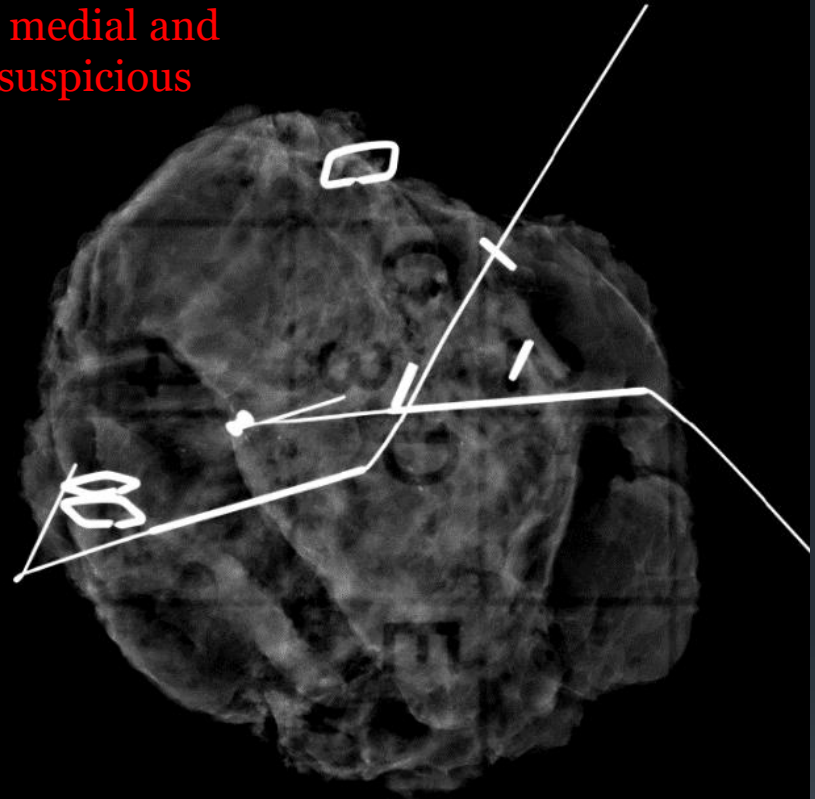
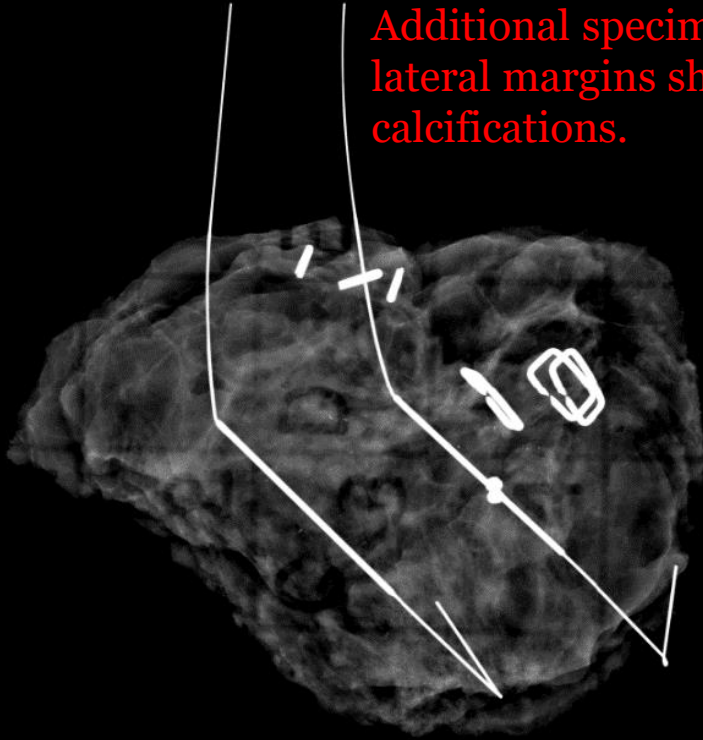


Calcifications are located within the medial breast less than 1/3 anterior depth. Thus, short (5 cm) Kopans wires were placed with a medial to lateral approach.



# Wire Localization Case One (continued)

Additional specimens from medial and lateral margins showed no suspicious calcifications.

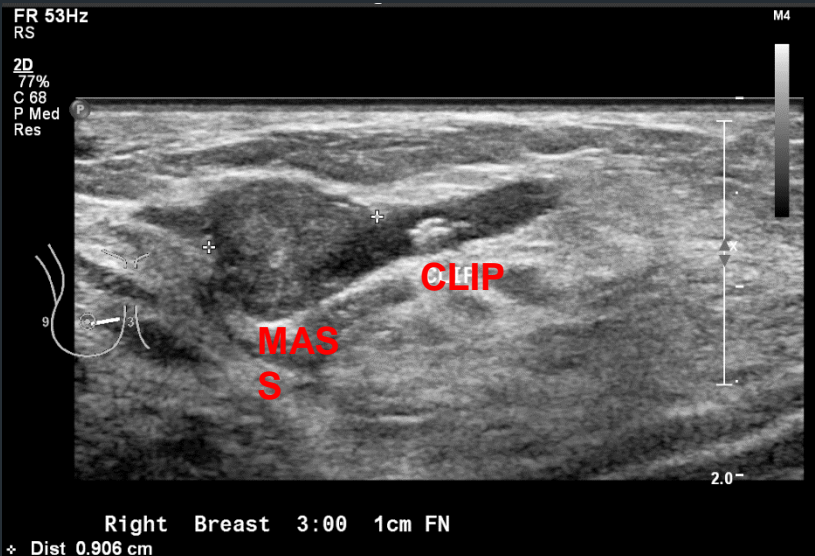


Post-procedure mammogram demonstrates parallel wires bracketing the residual calcifications in the medial anterior breast.



# Wire Localization

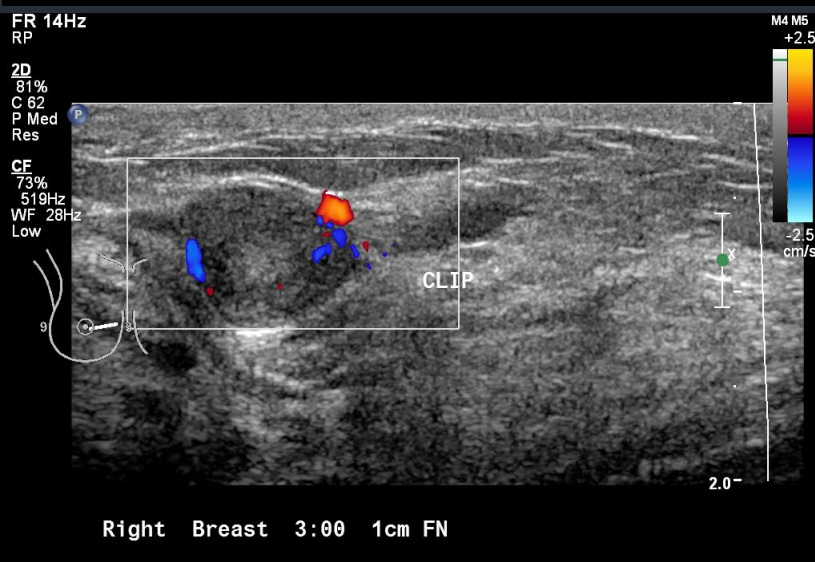
## Case Two: Ultrasound



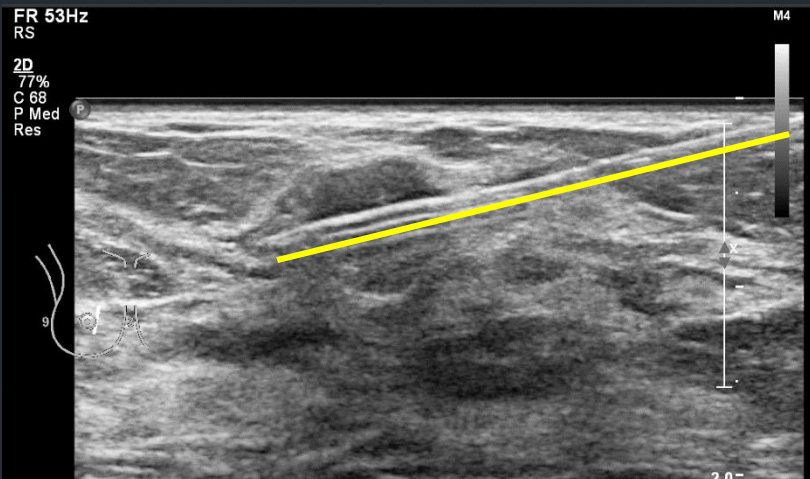
23-year-old with well-circumscribed mass within the right breast at 3:00, 1 cm from the nipple.

Pathology confirmed fibroepithelial lesion with extensive necrosis.

Excision was recommended to rule out Phyllodes tumor. The mass was amenable to ultrasound guided needle localization.

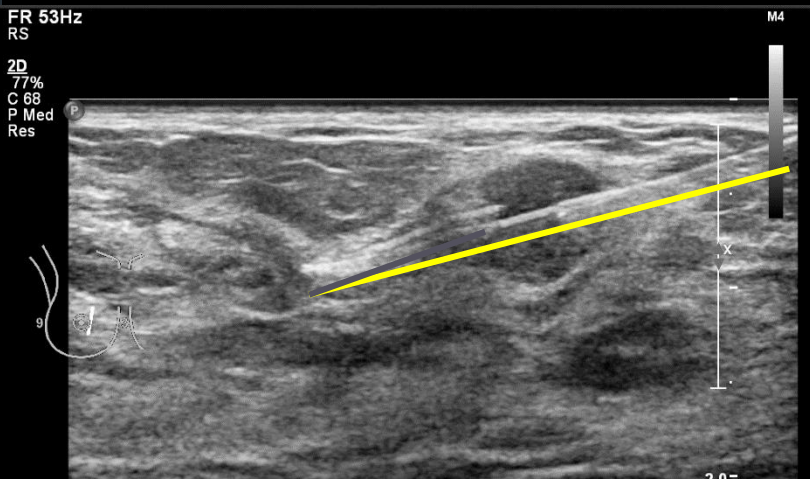


# Wire Localization Case Two (continued)



Right Breast 3:00 1cm FN PRE WIRE

Prior to ultrasound guided wire localization, the target mass was visualized on ultrasound and approach planned. This lesion is superficial and located medially, thus a short Kopans (7 cm) wire and a medial to lateral approach was chosen.



Right Breast 3:00 1cm FN POST WIRE

Under ultrasound guidance, the Kopans wire was placed through the lesion. The depth was adjusted so the needle tip is approximately 2 cm deep to the center of the target.

A spring wire was deployed and positioning was confirmed appropriate on sonography.

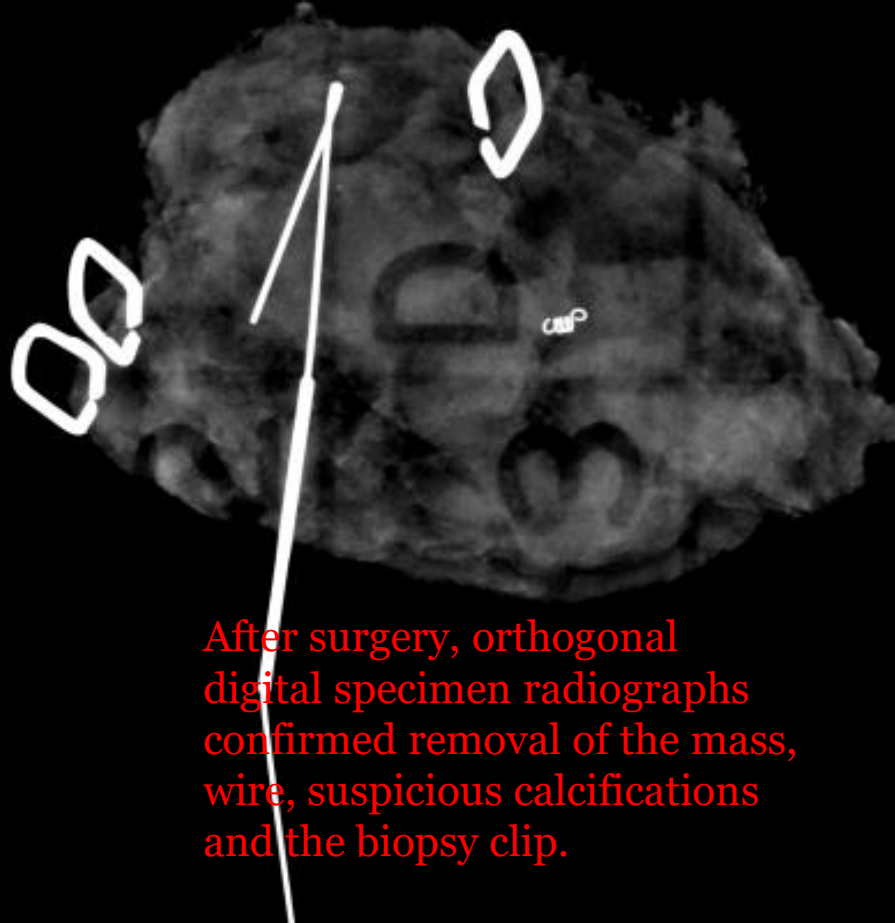
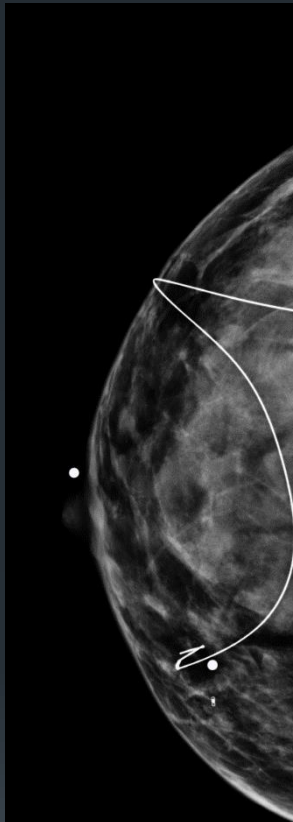


THE UNIVERSITY OF  
CHICAGO



# Wire Localization

## Case Two (continued)

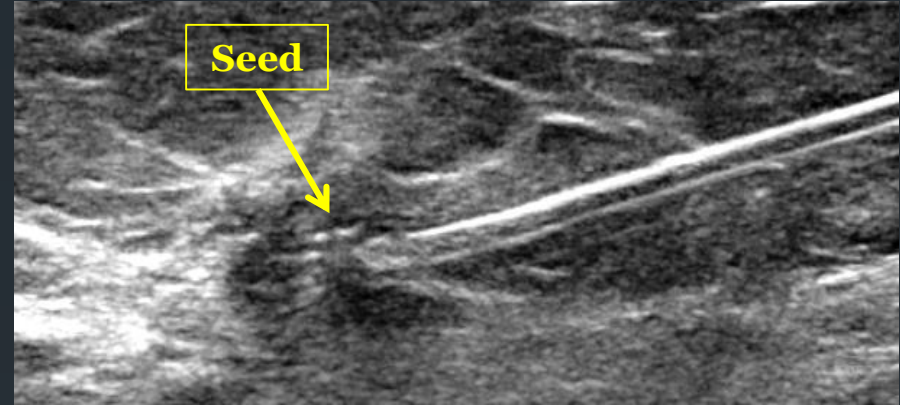
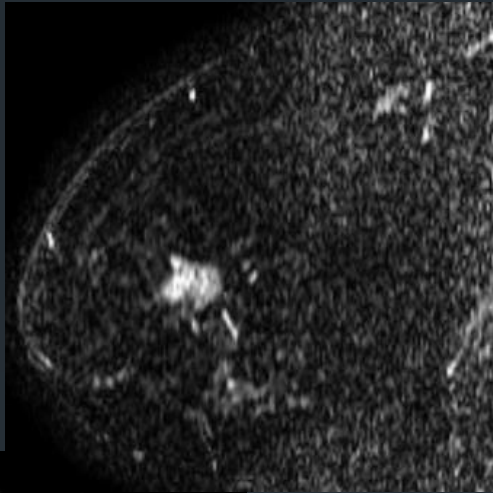


After surgery, orthogonal digital specimen radiographs confirmed removal of the mass, wire, suspicious calcifications and the biopsy clip.

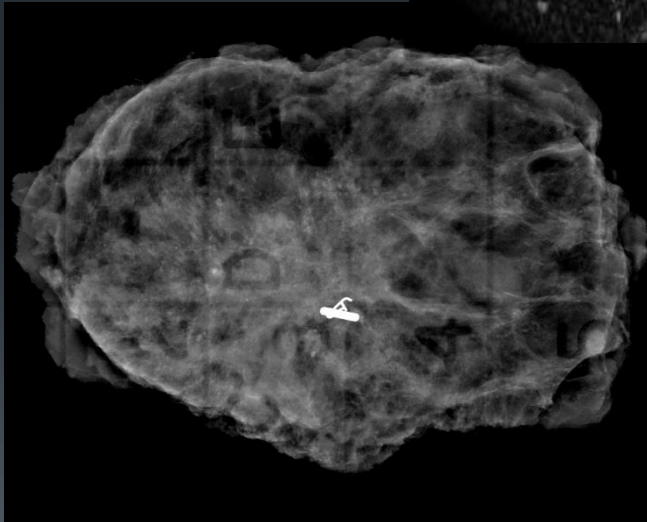
Post procedure mammogram confirmed appropriate wire placement. The mass is difficult to identify in this patient with heterogeneously dense breast tissue. However, the wire is positioned in the medial central breast, adjacent to the biopsy clip, at the expected position of the mass.

# Radioactive Seed Localization Case One (continued)

Coronal post contrast MRI image demonstrates an irregular-shaped known malignancy in the left breast at 3:00. RSL was then undertaken.

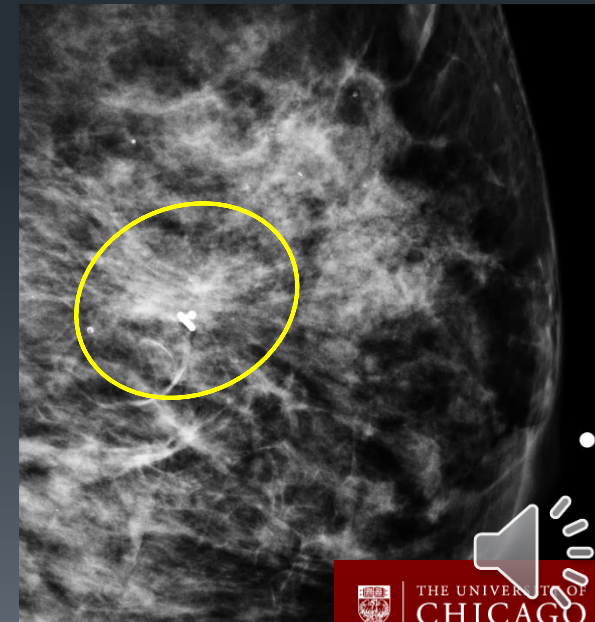


Needle in lesion, during seed deployment



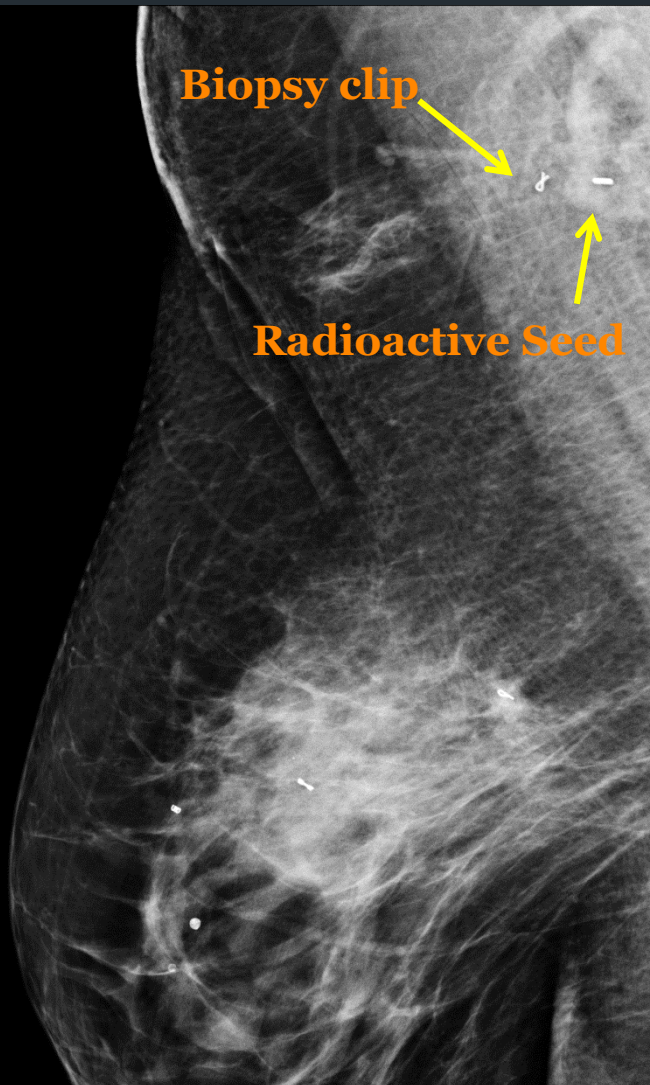
Digital specimen radiograph demonstrates successful removal of mass with clip and seed. An additional posterior margin was taken (not imaged). Margins were negative on pathology.

Radioactive seed in appropriate position in the left breast mass adjacent to biopsy clip.

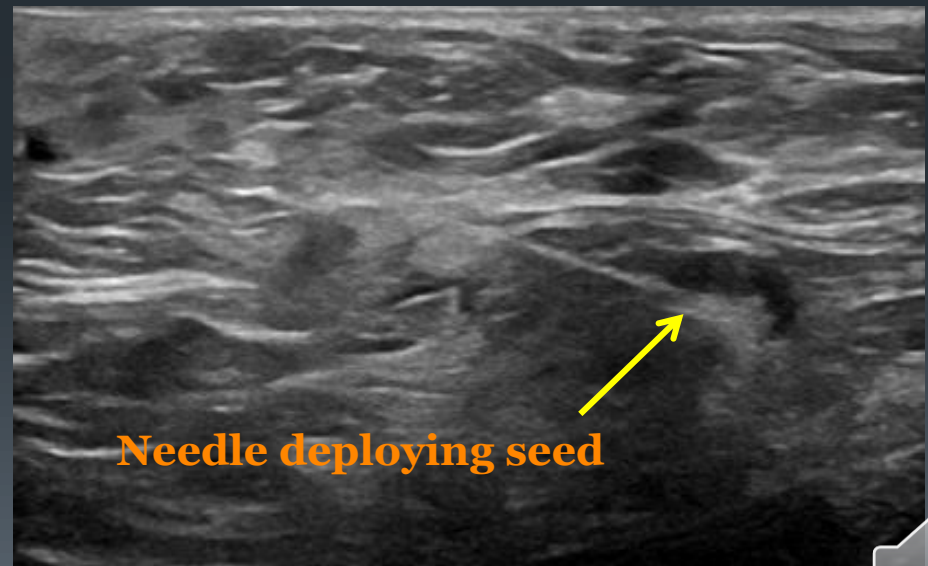


# Radioactive Seed Localization

## Case Three: Lymph Node



- 52 year old woman with history of right breast cancer presented to surgery clinic with a palpable right axillary lymph node.
- Ultrasound-guided biopsy was performed, and a clip was placed.
- Subsequently, seed localization was performed, for resection of the mass and right axillary lymph node.



Ultrasound guided seed placement

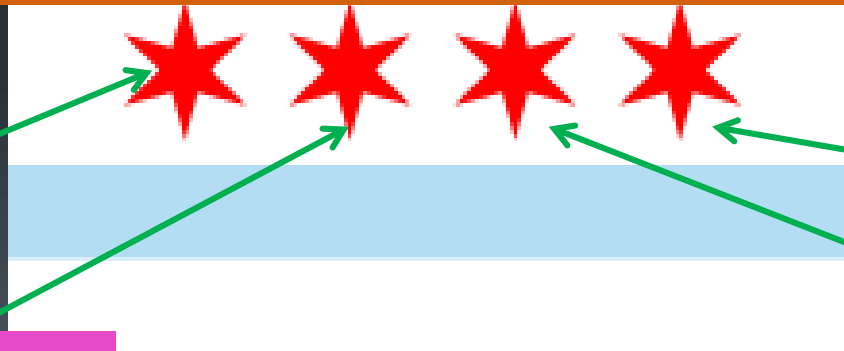



# Trivia time!

THANK YOU  
Questions?  
EMAIL:

[kkulkarni@radiology.bsd.uchicago.edu](mailto:kkulkarni@radiology.bsd.uchicago.edu)



Fort Dearborn

Great Chicago Fire 1871

World's Columbian Exposition

Chicago World's Fair



THE UNIVERSITY OF  
CHICAGO

